



PATIENT PRESENTING CLINICAL SIGNS

Bruce Ostrower History: 10 y papillon presented for falling down two sets of steps yesterday and hurt his right hip/ leg. pet was will scream in pain when touched. o gave gaba and cannapet yesterday and pet slept thru the night. today they gave nothing by mouth thinking he would get surgery today.

SPECIES Abnormal PE/Chem/CBC/UA Results: Physical Examination Key -- (N= Normal, A= Abnormal)
Canine CV/Respiratory: Normal heart rate and rhythm, no murmur, pulses strong and synchronous, normal bronchovesicular sounds. EENT: Clear OU and AU. No nasal discharge. No cough on tracheal palpation. Oral cavity: Unable to examine-muzzled Musculoskeletal: BCS = 5/9. Ambulatory x 3. Grade 5/5 RH lameness (non-WB). Unable to do ortho exam w/out sedation. Uro/Perineum: No significant lesions
BREED Abd/GI: Tense, non-painful. No masses or fluid wave palpated Lymph Nodes: No peripheral lymphadenopathy Neurological: Alert and appropriate. No significant abnormalities Skin: Good hair coat. No ectoparasites seen Mentation: BAR Hydration: N Assessment: Hx of L FHO Caudoventral luxation of R femoral head.

SEX RADIOGRAPHIC STUDY OF THE PELVIS

NM Radiographs of the pelvis in two orthogonal imaging planes are provided for review.

RADIOGRAPHIC FINDINGS

The osseous and surrounding soft tissue structures of the pelvis are within normal limits.

AGE

10 Years The left femoral head is absent and the left femur is in a relative proximal position. The osteotomy of the left femoral neck has rounded margins.

INTERPRETED BY

The right femoral head is luxated caudoventrally, the right femoral head is superimposed on the right obturator foramen in the VD projection.

Sebastian Schaub, DVM
 Dr. med. vet. DipECVDI

RADIOGRAPHIC DIAGNOSIS

- Right sided caudoventral coxofemoral luxation
- History of left sided femoral head ostectomy

HOSPITAL NAME

DPC Veterinary Hospital

INTERPRETATION OF THE FINDINGS & FURTHER RECOMMENDATIONS

Due to recent trauma, closed reduction would be an option. Surgical options can be discussed if there is recurrent coxofemoral luxation.

REFERRING VET

Dr. Rivera

INVOICE

59118

DATE

7-1-23



PATIENT

Bruce Ostrower

SPECIES

Canine

BREED

Papillon

SEX

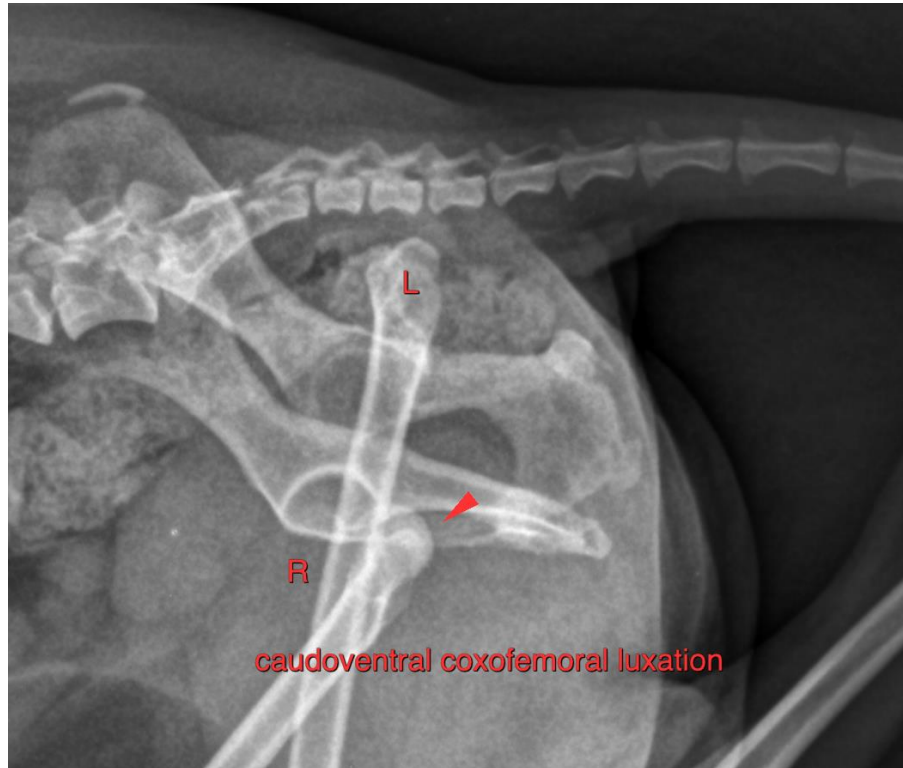
NM

AGE

10 Years

INTERPRETED BY

Sebastian Schaub, DVM
Dr. med. vet. DipECVDI



HOSPITAL NAME

DPC Veterinary
Hospital

The information and recommendations provided are based on the images presented by the referring veterinarian/sonographer. No evaluation can be communicated regarding pathology that was not visible in the image/video clips provided.

REFERRING VET

Dr. Rivera

Thank you for this referral. If the clinical or image interpretation does not parallel your findings or if I can be of any further assistance please contact me.

Sebastian Schaub, Sebastian Schaub, DVM, Dr. med. vet. DipECVDI
info@sonopath.com

INVOICE

59118

DATE

7-1-23