



#### PATIENT

Walter Darling

#### PRESENTING CLINICAL SIGNS

History: intermittent limp on LRL associated with hard play/exercise and improves with rest. Limp has become more frequent over past few weeks.

#### SPECIES

Canine

Abnormal PE/Chem/CBC/UA Results: No lameness noted on exam. Resistant for hip extension bilaterally

#### BREED

Welsh Corgi

#### RADIOGRAPHIC STUDY OF THE PELVIS

A ventrodorsal projection of the pelvis is provided for review.

#### RADIOGRAPHIC FINDINGS

There is a breed specific chondrodystrophic conformation of the osseous structures.

#### SEX

Neutered Male

The osseous and surrounding soft tissue structures of the pelvis are within normal limits. Both coxofemoral joints present smooth osseous margins and congruent joint spaces.

The left stifle joint presents evidence of mild osteophyte new bone formation.

#### AGE

4 Years

#### RADIOGRAPHIC DIAGNOSIS

- Normal pelvis and coxofemoral joints

#### INTERPRETATION OF THE FINDINGS & FURTHER RECOMMENDATIONS

#### INTERPRETED BY

Sebastian Schaub,  
DVM Dr. med. vet.  
DipECVDI

The radiographic study of the pelvis presents without abnormalities.

There is evidence of mild degenerative joint disease of the left stifle joint – check for pathology such as cranial cruciate ligament pathology.

#### HOSPITAL NAME

Companion AC

**The information and recommendations provided are based on the images presented by the referring veterinarian/sonographer. No evaluation can be communicated regarding pathology that was not visible in the image/video clips provided.**

#### REFERRING VET

Dr. Acosta

Thank you for this referral. If the clinical or image interpretation does not parallel your findings or if I can be of any further assistance please contact me.

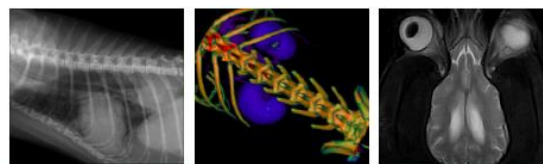
**Sebastian Schaub**, Sebastian Schaub, DVM, Dr. med. vet. DipECVDI  
sebast.schaub@gmail.com

#### INVOICE

16421

#### DATE

7/1/22



**PATIENT**

Walter Darling

**SPECIES**

Canine

**BREED**

Welsh Corgi

**SEX**

Neutered Male

**AGE**

4 Years

**INTERPRETED BY**

Sebastian Schaub,  
DVM Dr. med. vet.  
DipECVDI

**HOSPITAL NAME**

Companion AC

**REFERRING VET**

Dr. Acosta

**INVOICE**

16421

**DATE**

7/1/22