



**PATIENT PRESENTING CLINICAL SIGNS**

**Bebe Campos** History: Presented for decreased activity, lethargy, not wanting to go up and down the stairs for 24 hours. P had anal glands expressed with a nurse yesterday and started acting different a few hours later. P has history of bilateral MPL repair and microvascular liver dysplasia.

**SPECIES**

**Canine** Abnormal PE/Chem/CBC/UA Results: 7/1/22 - ALB 4.5 (2.5-4.4) H, GLU 124 60-110) H, GLOB 1.9 (2.3-5.2) L, RBC 9.06 (5.5-8.5) H, HCT 57.8 (37-57) H. Painful on palpation of the thoracic and thoraco-lumbar spine. Repeatable. No CP deficits or other neurological abnormalities noted.

**BREED RADIOGRAPHIC STUDY OF THE THORACIC SPINE**

**Terrier Mix** Radiographs of the thoracic spine in two orthogonal imaging planes are provided for review.

**SEX RADIOGRAPHIC FINDINGS**

**Spayed Female** In the radiographic study centered on the thoracic spine, a moderate soft tissue swelling is seen at the caudodorsal aspect of the neck with small, interspersed gas bubbles - suspect preceding subcutaneous injection/infusion.

**AGE**

**4 Years** The osseous structures of the thoracic spine are within normal limits.  
The intervertebral disc space L1/L2 is moderately narrowed.

**INTERPRETED BY RADIOGRAPHIC DIAGNOSIS**

**Sebastian Schaub, DVM Dr. med. vet. DipECVDI**

- Suspect discopathy L1/L2
- Normal thoracic spine

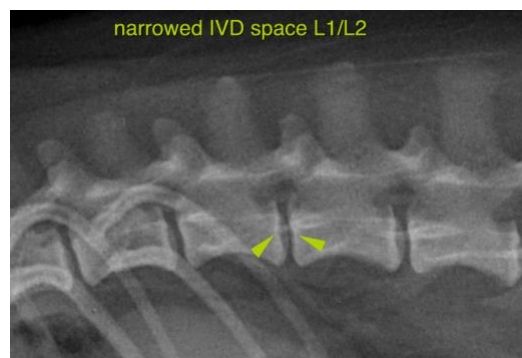
**INTERPRETATION OF THE FINDINGS & FURTHER RECOMMENDATIONS**

**HOSPITAL NAME**

**Boca Park AH** The narrowed intervertebral disc space L1/L2 is suggestive for discopathy that might or might not be associated with compressive myelopathy. If clinical signs are refractory to therapy or neurological deficits develop, cross-sectional imaging of the spine is recommended.

**REFERRING VET**

**Dr. Ashman**



**INVOICE**

16417

**DATE**

7/1/22



**PATIENT**

Bebe Campos

**The information and recommendations provided are based on the images presented by the referring veterinarian/sonographer. No evaluation can be communicated regarding pathology that was not visible in the image/video clips provided.**

**SPECIES**

Canine

Thank you for this referral. If the clinical or image interpretation does not parallel your findings or if I can be of any further assistance please contact me.

**BREED**

Terrier Mix

**Sebastian Schaub**, Sebastian Schaub, DVM, Dr. med. vet. DipECVDI  
sebast.schaub@gmail.com

**SEX**

Spayed Female

**AGE**

4 Years

**INTERPRETED BY**

Sebastian Schaub,  
DVM Dr. med. vet.  
DipECVDI

**HOSPITAL NAME**

Boca Park AH

**REFERRING VET**

Dr. Ashman

**INVOICE**

16417

**DATE**

7/1/22