



PATIENT PRESENTING CLINICAL SIGNS

Sandy Marques History: Fast-growing swelling/mass on Right shoulder. The owner first noticed it 2 weeks ago. Hx of chronic Right forelimb lameness that would only last a few days. Pet is still ambulatory x 4, mass does not appear painful.

SPECIES COMPUTED TOMOGRAPHIC STUDY OF THE THORAX

Canine A high resolution pre- and post-contrast CT study of the thorax is provided for review.

BREED COMPUTED TOMOGRAPHIC FINDINGS

Maltese Mix Centered on the supraspinatus fossa of the right scapula, an ill-defined, soft tissue attenuating and heterogeneous contrast enhancing mass is appreciated. The mass in the right supraspinatus fossa is measuring approximately 3.5 x 3.0 x 6.0 cm in size and is extending distally up to the level of the major tubercle of the right humerus. The supraspinatus fossa of the right scapula is mildly deviated medially and presents with moth eaten osteolytic lesions. The major tubercle of the right humerus presents a crescent shaped prominent depression of the medial cortex.

SEX

Spayed Female

AGE

13 Years 10 Months

The right superficial cervical lymph node and right axillary lymph nodes are prominent, uniform soft tissue attenuating and mild heterogeneous contrast enhancing.

In the subcutaneous tissue at the left ventrolateral thoracic wall, a well-defined, ovoid shaped lipoma measuring up to 14 mm in size is visible.

INTERPRETED BY

Sebastian Schaub, DVM
Dr. med. vet. DipECVDI

The sternal, cranial mediastinal and tracheobronchial lymph nodes are small elongated with a normal short-to-long-axis-ratio is < 0.5, the attenuation and contrast enhancement pattern is uniform and considered within normal limits.

HOSPITAL NAME

Mobile Pet Imaging

The cardiovascular structures including the pulmonary vasculature are within normal limits.

The bronchial tree presents with regular branching and tapers uniformly towards the periphery as expected, the bronchial walls are thin and smooth. The bronchus-to-artery ratio is within normal limits.

REFERRING VET

Dr. Meaux

The lung parenchyma presents the expected architecture and attenuation behavior.

Small incidental gas pockets are seen within the esophageal lumen, there is no evidence of abnormal dilation.

INVOICE

15989

The left medial liver lobe presents convex shaped caudal margin and a intraparenchymal irregular ovoid shaped filling defect.

COMPUTED TOMOGRAPHIC DIAGNOSIS

DATE

6/11/22



PATIENT

Sandy Marques

- Soft tissue mass centered on the right supraspinatus fossa of the scapular with secondary polyostotic semi-aggressive osteolytic lesions and pressure erosion of the associated osseous structures
- Lymphadenopathy right axillary and right superficial cervical lymph node
- Enlarged and rounded left medial liver lobe with intraparenchymal cavitory lesion
- No evidence of pulmonary metastatic disease

SPECIES

Canine

INTERPRETATION OF THE FINDINGS & FURTHER RECOMMENDATIONS

BREED

Maltese Mix

The soft tissue mass within the supraspinatus fossa is compatible with soft tissue neoplasm and sarcoma is considered likely here. The prominent tributary lymph nodes are equivocal for metastatic spread versus reactive hyperplasia. As there is evidence of osseous involvement, surgical resection will warrant amputation of the right front limb including scapulectomy.

SEX

Spayed Female

The enlarged left medial liver lobe can represent regeneration nodule/nodular hyperplasia with hepatic cyst or neoplastic transformation (e.g. hepatocellular adenoma/carcinoma). Ultrasound guided FNA sampling can be used as advanced minimally invasive diagnostic tool.

AGE

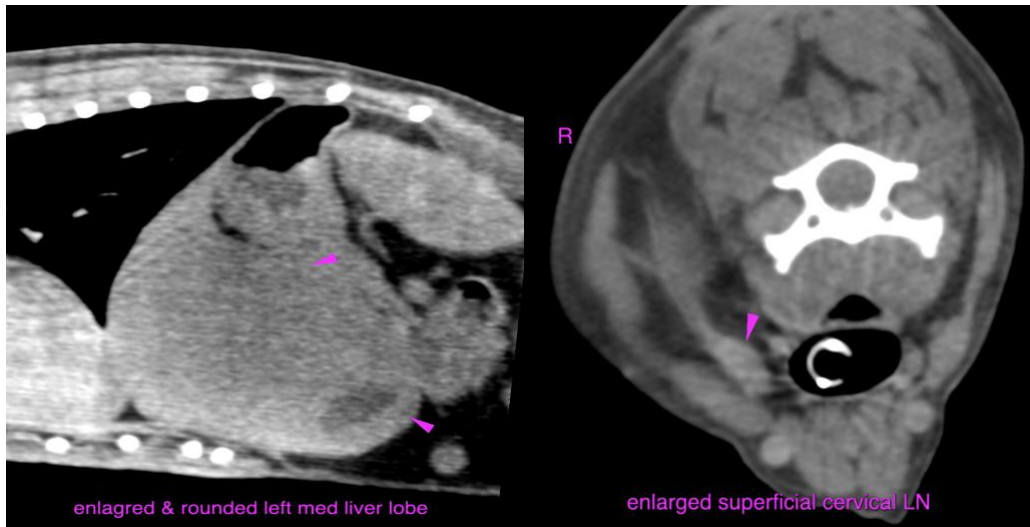
13 Years 10 Months

INTERPRETED BY

Sebastian Schaub, DVM
Dr. med. vet. DipECVDI

HOSPITAL NAME

Mobile Pet Imaging



enlarged & rounded left med liver lobe

enlarged superficial cervical LN

REFERRING VET

Dr. Meaux

INVOICE

15989

DATE

6/11/22



PATIENT

Sandy Marques

SPECIES

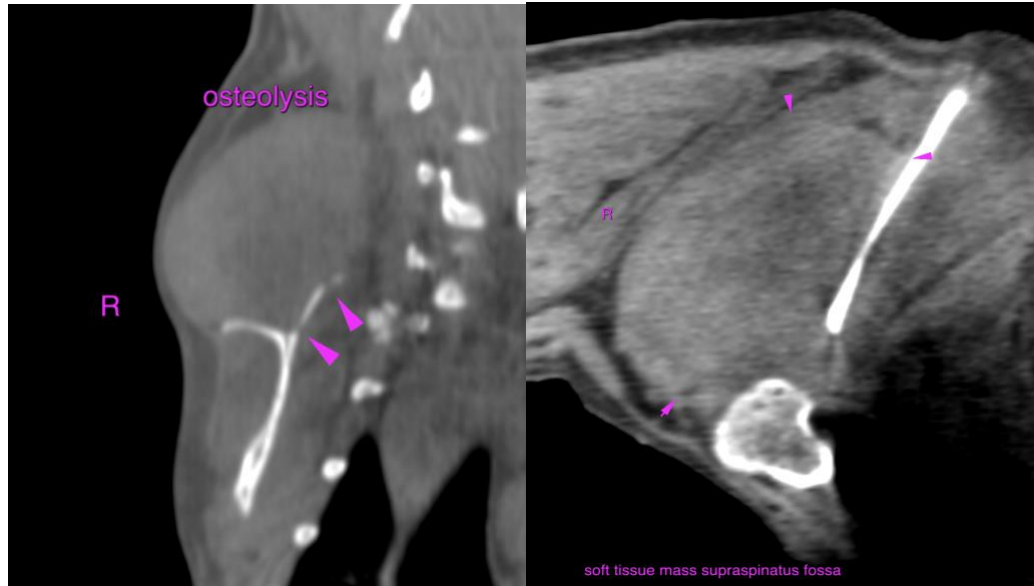
Canine

BREED

Maltese Mix

SEX

Spayed Female



AGE

13 Years 10 Months

The information and recommendations provided are based on the images presented by the referring veterinarian/sonographer. No evaluation can be communicated regarding pathology that was not visible in the image/video clips provided.

Thank you for this referral. If the clinical or image interpretation does not parallel your findings or if I can be of any further assistance please contact me.

INTERPRETED BY

Sebastian Schaub, DVM
Dr. med. vet. DipECVDI

Sebastian Schaub, Sebastian Schaub, DVM, Dr. med. vet. DipECVDI
sebast.schaub@gmail.com

HOSPITAL NAME

Mobile Pet Imaging

REFERRING VET

Dr. Meaux

INVOICE

15989

DATE

6/11/22