



PATIENT PRESENTING CLINICAL SIGNS

Mya Benzoni History: Vomited undigested food after ear cleaning but meal was 4 hrs prior.
Abnormal PE/Chem/CBC/UA Results:

SPECIES RADIOGRAPHIC STUDY OF THE ABDOMEN

Canine Radiographs of the abdomen in three imaging planes are provided for review.

RADIOGRAPHIC FINDINGS

BREED

Dachshund In the subcutaneous tissue of the right inguinal region, a mild soft tissue swelling with interspersed gas bubbles is appreciated – suspect preceding injection.

SEX

Female No abnormalities of the extraabdominal soft tissues are noted. The abdominal wall is smooth and thin.

The serosal detail is maintained throughout the peritoneal and retroperitoneal space.

The liver is appropriate in position, size and presents uniform opacity.

AGE

4 Months The splenic head is in the anticipated position and within normal limits for size and opacity. The splenic body and tail are considered normal for position, size, shape and opacity.

Both kidneys are seen and present with normal size, shape, delineation and opacity. The urinary bladder is in its anticipated position. No radiopaque calculi are noted throughout the upper and lower urinary tract.

INTERPRETED BY

Sebastian Schaub,
DVM Dr. med. vet.
DipECVDI

The stomach is in its anticipated position and contains a small amount of fluid.

HOSPITAL NAME

The small intestinal loops are of even diameter and non-dilated, a small amount of foamy material within the small intestinal loops is noted.

Northvale VC

The colon is seen in the expected position and presents with appropriate content.

RADIOGRAPHIC DIAGNOSIS

REFERRING VET

- Mild fluid filled stomach

Dr. Stefanie Simon

INTERPRETATION OF THE FINDINGS & FURTHER RECOMMENDATIONS

INVOICE

16020

The mild fluid filled stomach can indicate gastric emptying disorder if there wasn't recent fluid intake by the patient. There is no evidence of radiopaque foreign material or signs for intestinal mechanical obstruction. Overall, I consider the odds for gastritis or dietary indiscretion high. If clinical signs are refractory to therapy, recommend follow up radiographs or a complete abdominal ultrasound examination.

DATE

6/9/22



PATIENT

Mya Benzoni

SPECIES

Canine

BREED

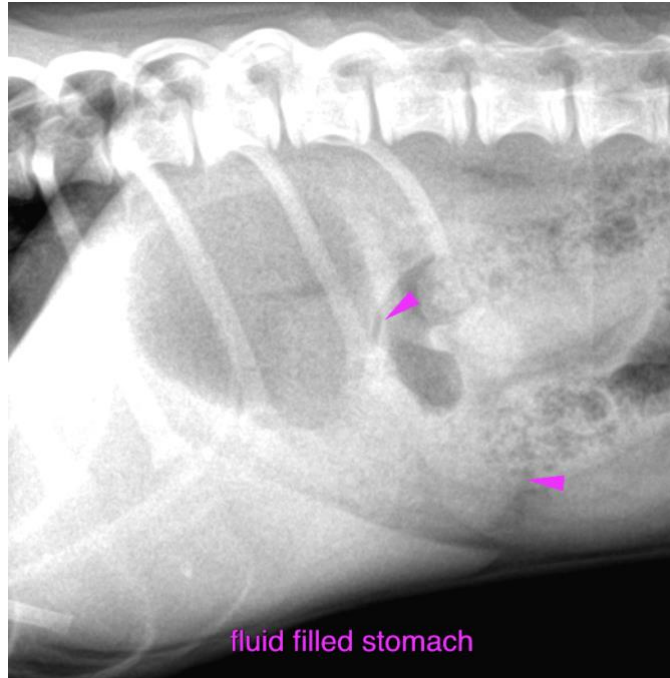
Dachshund

SEX

Female

AGE

4 Months



The information and recommendations provided are based on the images presented by the referring veterinarian/sonographer. No evaluation can be communicated regarding pathology that was not visible in the image/video clips provided.

INTERPRETED BY

Sebastian Schaub,
DVM Dr. med. vet.
DipECVDI

Thank you for this referral. If the clinical or image interpretation does not parallel your findings or if I can be of any further assistance please contact me.

HOSPITAL NAME

Northvale VC

Sebastian Schaub, Sebastian Schaub, DVM, Dr. med. vet. DipECVDI
sebast.schaub@gmail.com

REFERRING VET

Dr. Stefanie Simon

INVOICE

16020

DATE

6/9/22