



PATIENT

Zasha #01136
Abdominal Study

SPECIES

Canine

BREED

Mixed Breed

SEX

Female

AGE

12Y

WEIGHT

42lbs

INTERPRETED BY

Sebastian Schaub, DVM
Dr. med. vet.
DipECVDI

IMAGING PERFORMED BY

Alondra Aviles Lopez
VT

HOSPITAL NAME

Veterinary Image
Center

REFERRING VET

Dra. Vazquez, DVM

INVOICE

75325

DATE

6-8-26

PRESENTING CLINICAL SIGNS

Patient presented for Left Liver Mass and History of Elevated Liver Enzymes. FNA results most suggestive of a well differentiated hepatocellular carcinoma.

Abnormal PE/Chem/CBC/UA Results: CHEM: ALT:329 (10-125) CHOL: 393 (110-320)

COMPUTED TOMOGRAPHY OF THE ABDOMEN

A high resolution pre- and post-contrast CT study of the abdomen is provided for review.

COMPUTED TOMOGRAPHIC FINDINGS

The serosal fat presents normal attenuation behavior. There is no evidence of peritoneal effusion or peritonitis.

In the ventral aspect of the left kidney, a well-defined, roundish fluid attenuating lesions is seen; measuring 2.6 cm in diameter, protruding beyond the renal surface.

The adrenal glands are within normal limits for size, shape and organ architecture.

The spleen presents with normal shape, even surface, uniformly attenuating parenchyma and has a heterogeneous contrast enhancement pattern, presenting multiple hyperattenuating intraparenchymal nodules.

Originating from the left lateral liver lobe, an irregular shaped, uniform soft tissue attenuating and heterogeneous contrast enhancing mass is seen; measuring 9.7 x 11.2 x 13.7 cm. The left divisional hepatic mass is protruding caudally into the left abdominal quadrant, and the gastric axis is deviated caudally by the mass effect.

The pancreas is evenly contoured; the pancreatic parenchyma is homogeneous and presents uniform contrast enhancement.

The position, delineation, wall and content of the gastrointestinal tract are considered within normal limits throughout.

Multiple intervertebral discs along the lumbar spine are protruding into the vertebral canal, occupying approximately ≤ 15% of the cross-sectional area of the vertebral canal at the same level.

COMPUTED TOMOGRAPHIC DIAGNOSIS

- Left divisional hepatic soft tissue mass – likely originating from the left lateral liver lobe
- Irregular contrast enhancing splenic parenchyma
- Simple renal cyst left kidney

INTERPRETATION OF THE FINDINGS & FURTHER RECOMMENDATIONS

The hepatic soft tissue mass is fitting the history of hepatocellular carcinoma originating from the left lateral liver lobe. Surgical management via lobectomy of the affected liver lobes appears feasible.

The heterogeneous contrast enhancement pattern of the splenic parenchyma is most suggestive for nodular hyperplasia or extramedullary hematopoiesis. FNA sampling of the spleen may be used to rule out malignant infiltrative disease entirely.



PATIENT

Zasha #01136
Abdominal Study

SPECIES

Canine

BREED

Mixed Breed

SEX

Female

AGE

12Y

WEIGHT

42lbs

INTERPRETED BY

Sebastian Schaub, DVM
Dr. med. vet.
DipECVDI

IMAGING PERFORMED BY

Alondra Aviles Lopez
VT

HOSPITAL NAME

Veterinary Image
Center

REFERRING VET

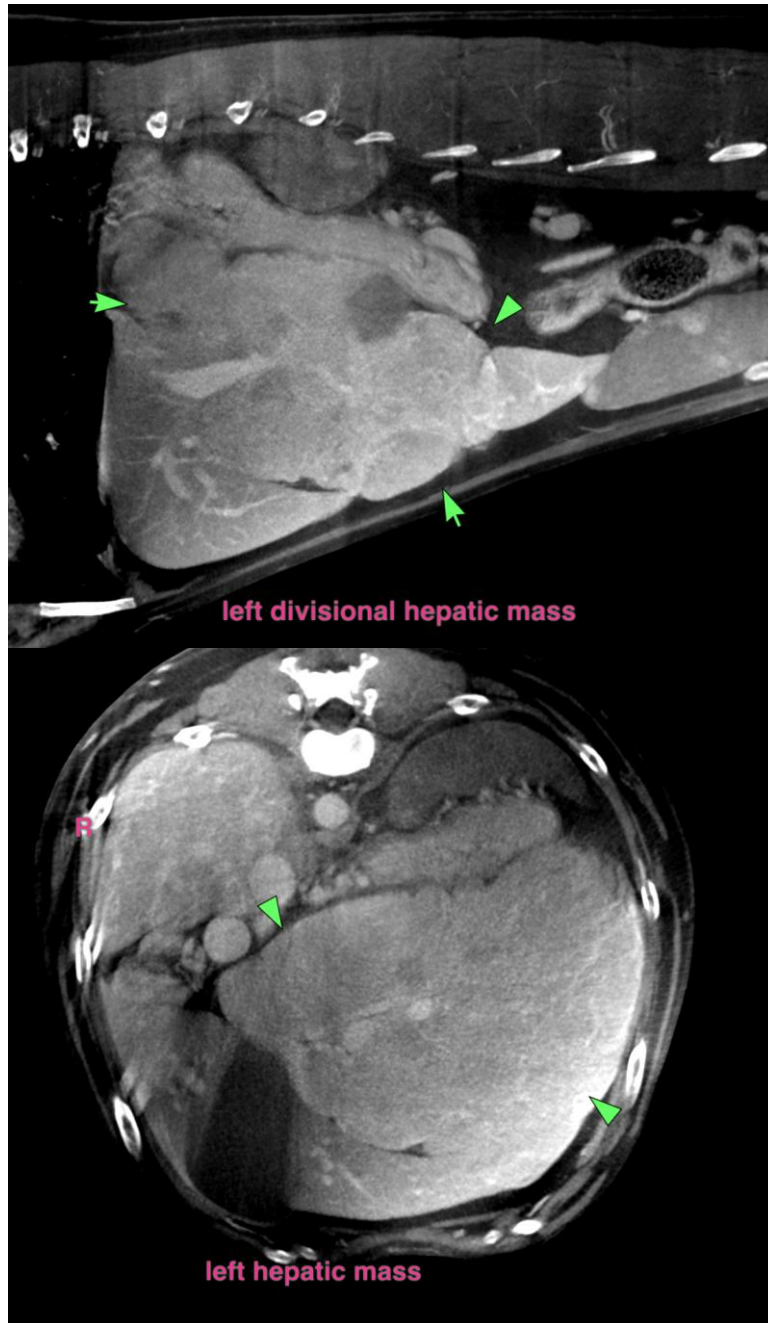
Dra. Vazquez, DVM

INVOICE

75325

DATE

6-8-26





PATIENT

Zasha #01136
Abdominal Study

SPECIES

Canine

BREED

Mixed Breed

SEX

Female

AGE

12Y

WEIGHT

42lbs

INTERPRETED BY

Sebastian Schaub, DVM
Dr. med. vet.
DipECVDI

IMAGING PERFORMED BY

Alondra Aviles Lopez
VT

HOSPITAL NAME

Veterinary Image
Center

REFERRING VET

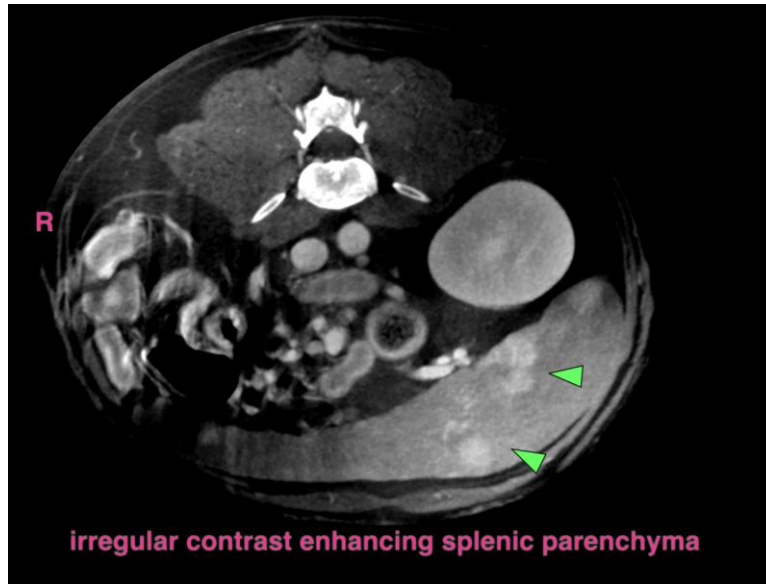
Dra. Vazquez, DVM

INVOICE

75325

DATE

6-8-26



The information and recommendations provided are based on the images presented by the referring veterinarian/sonographer. No evaluation can be communicated regarding pathology that was not visible in the image/video clips provided.

Thank you for this referral. If the clinical or image interpretation does not parallel your findings or if I can be of any further assistance please contact me.

Sebastian Schaub, Sebastian Schaub, DVM, Dr. med. vet. DipECVDI
info@sonopath.com