



**PATIENT**

Ruhi Padam

**PRESENTING CLINICAL SIGNS**

3 weeks ago during the evening walk, Ruhi met a neighborhood dog and were playing together. Either the way Ruhi got up or if she hit her leg, she started screaming. went to emergency hospital who diagnosed as acute CCL of left hind leg and should be referred to a specialist for surgery without performing x-ray or drawer test at that visit . she came to our clinic today for x- ray and drawer test which looks negative to us . currently on Gabapentin BID and Metacam SID with rest and still limping

**SPECIES**

Canine

**RADIOGRAPHIC STUDY OF THE PELVIS AND LEFT STIFLE JOINT**

**BREED**

Radiographs of the pelvis and the left stifle joint in two imaging planes are provided for review.

Labrador Retriever  
Mix

**RADIOGRAPHIC FINDINGS**

The osseous and surrounding soft tissue structures of the pelvis are within normal limits. The right femoral neck presents a prominent Morgan line.

**SEX**

F

The volume of the soft tissue shadow of the left thigh musculature is moderately decreased.

The patella of the left stifle joint is superimposed on the medial femoral condyle. The left stifle joint presents a mild intracapsular soft tissue swelling.

**AGE**

12 Months

**RADIOGRAPHIC DIAGNOSIS**

- Left sided medial patellar luxation
- Mild articular swelling left stifle joint
- Disuse atrophy right thigh musculature
- Mild degenerative osteoarthritis right coxofemoral joint

**INTERPRETED BY**

Sebastian Schaub, DVM  
Dr. med. vet. DipECVDI

**INTERPRETATION OF THE FINDINGS & FURTHER RECOMMENDATIONS**

The main finding is the left sided medial patellar luxation of the left stifle joint – commonly congenital/developmental in origin. In combination with the history, a traumatic insult may have caused tearing/stretching of the joint capsule & fascia causing instability.

**HOSPITAL NAME**

Brittany Glen Animal  
Hospital

**REFERRING VET**

Dr. Boktor

**INVOICE**

52382

**DATE**

6-8-22



**PATIENT**

Ruhi Padam

**SPECIES**

Canine

**BREED**

Labrador Retriever  
Mix

**SEX**

F

**AGE**

12 Months

**INTERPRETED BY**

Sebastian Schaub, DVM  
Dr. med. vet. DipECVDI

**HOSPITAL NAME**

Brittany Glen Animal  
Hospital

**REFERRING VET**

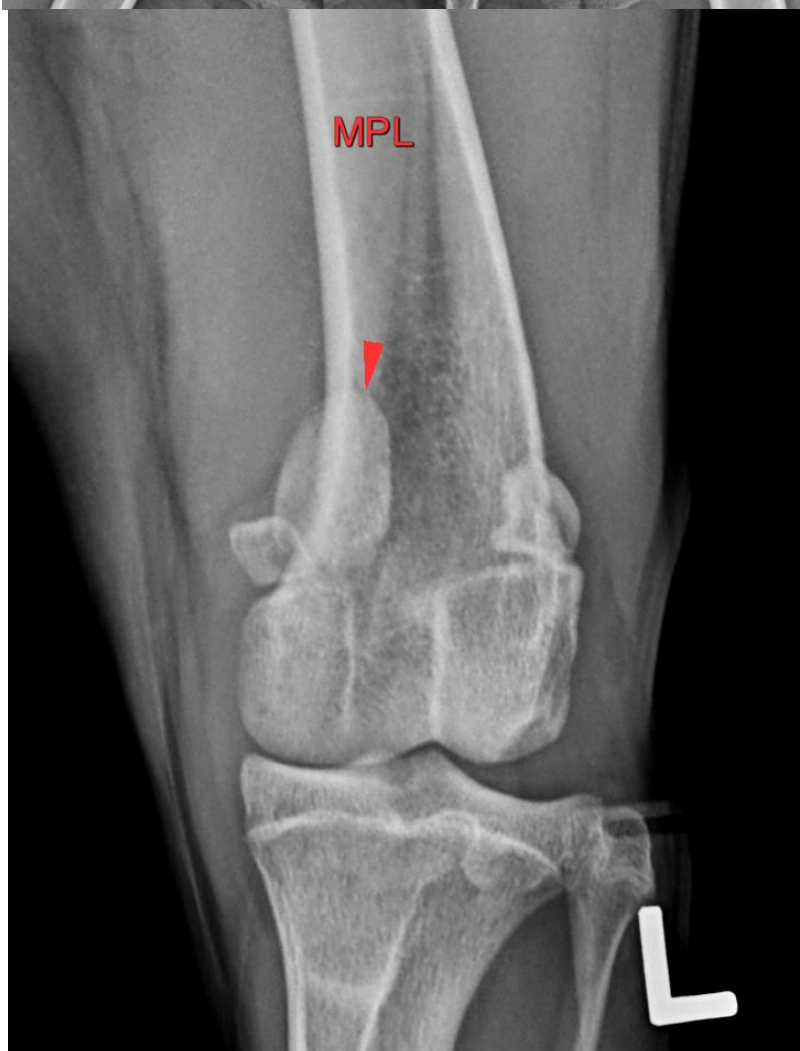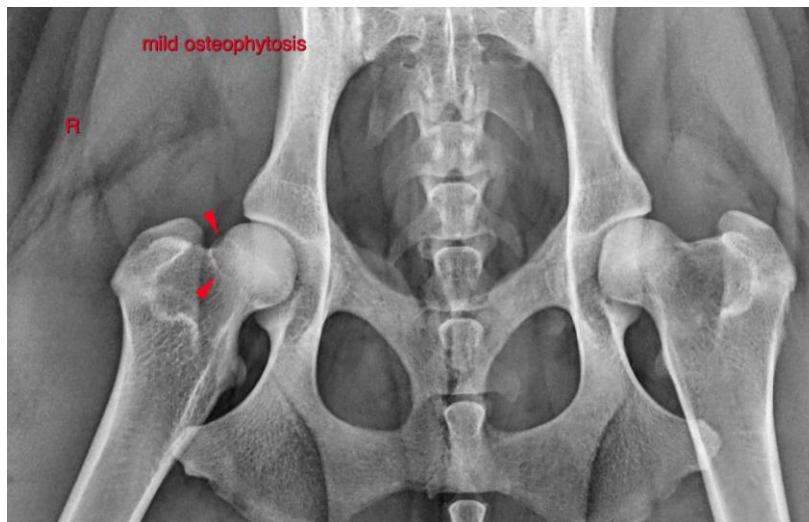
Dr. Boktor

**INVOICE**

52382

**DATE**

6-8-22





**PATIENT**

Ruhi Padam

The information and recommendations provided are based on the images presented by the referring veterinarian/sonographer. No evaluation can be communicated regarding pathology that was not visible in the image/video clips provided.

**SPECIES**

Canine

Thank you for this referral. If the clinical or image interpretation does not parallel your findings or if I can be of any further assistance please contact me.

**Sebastian Schaub**, Sebastian Schaub, DVM, Dr. med. vet. DipECVDI  
sebast.schaub@gmail.com

**BREED**

Labrador Retriever  
Mix

**SEX**

F

**AGE**

12 Months

**INTERPRETED BY**

Sebastian Schaub, DVM  
Dr. med. vet. DipECVDI

**HOSPITAL NAME**

Brittany Glen Animal  
Hospital

**REFERRING VET**

Dr. Boktor

**INVOICE**

52382

**DATE**

6-8-22