



PATIENT PRESENTING CLINICAL SIGNS

Louie Gitter Unilateral bloody nasal discharge. Recently had anal gland saccullectomy for adenocarcinoma.

COMPUTED TOMOGRAPHY OF THE SKULL

SPECIES A high resolution pre- and post-contrast CT study of the skull is provided for review.

Canine **COMPUTED TOMOGRAPHIC FINDINGS**

BREED All teeth but triadan 103, 104, 203, 204, 304, 309, 404 and 409 are absent. Triadan 104 presents a moderate widening of the periodontal space, and the root is perforating the right nasal cavity. The alveolar process of the right maxillary bone presents with moth eaten osteolytic lesions, approximately level with absent triadan 106&107. The horizontal plate of the palatine bone, R>L, presents moth eaten osteolytic lesion. The distal root of triadan 309 presents a moderate widening of the periodontal space.

Maltese Mix

SEX The right nasal cavity is occupied by non-contrast enhancing soft tissue material and post contrast administration, moderate thickening of the right nasal mucosal lining is appreciated. There is advanced loss of the conchal & turbinate structures of the right nasal cavity.

MN

Both temporomandibular joints present congruent joint spaces with even subchondral bone surfaces and are considered within normal limits.

AGE The right tympanic bulla contains a small amount of fluid attenuating material. The osseous lining of the right tympanic bulla is moderately thickened and smooth.. The external ear canals are within normal limits.

13 Years

INTERPRETED BY

Sebastian Schaub, DVM
Dr. med. vet. DipECVDI

The brain presents no deviation from normal anatomy and symmetry. The brain parenchyma is homogeneous and within normal limits for attenuation and distribution of contrast enhancement. The ventricular system is non-dilated and symmetric.

The right mandibular and medial retropharyngeal lymph nodes are prominent. The medial retropharyngeal lymph node bilaterally present evidence of mild mineralization.

HOSPITAL NAME COMPUTED TOMOGRAPHIC DIAGNOSIS

Mobile Pet Imaging
CFL

- Advanced periodontal disease triadan 104 with oronasal fistula formation
- Right sided destructive rhinitis and polyostotic semiaggressive osteolytic lesions of the surrounding osseous structures
- Periodontal disease 309
- Lymphadenopathy right mandibular lymph nodes
- Chronic mild right sided otitis media
- Mild dystrophic mineralization medial retropharyngeal lymph nodes bilaterally, incidental

REFERRING VET

Borecky

INVOICE INTERPRETATION OF THE FINDINGS & FURTHER RECOMMENDATIONS

52378 The findings are compatible with oronasal fistula formation triadan 104 with secondary right sided odontogenic destructive rhinitis and osteitis and reactive hyperplasia of the tributary lymph nodes. Recommend extraction of triadan 104. Biopsy from the alveolar crest/right nasal cavity can be used to rule out malignant infiltration entirely.

DATE

6-8-22



PATIENT

Louie Gitter

SPECIES

Canine

BREED

Maltese Mix

SEX

MN

AGE

13 Years

INTERPRETED BY

Sebastian Schaub, DVM
Dr. med. vet. DipECVDI

HOSPITAL NAME

Mobile Pet Imaging
CFL

REFERRING VET

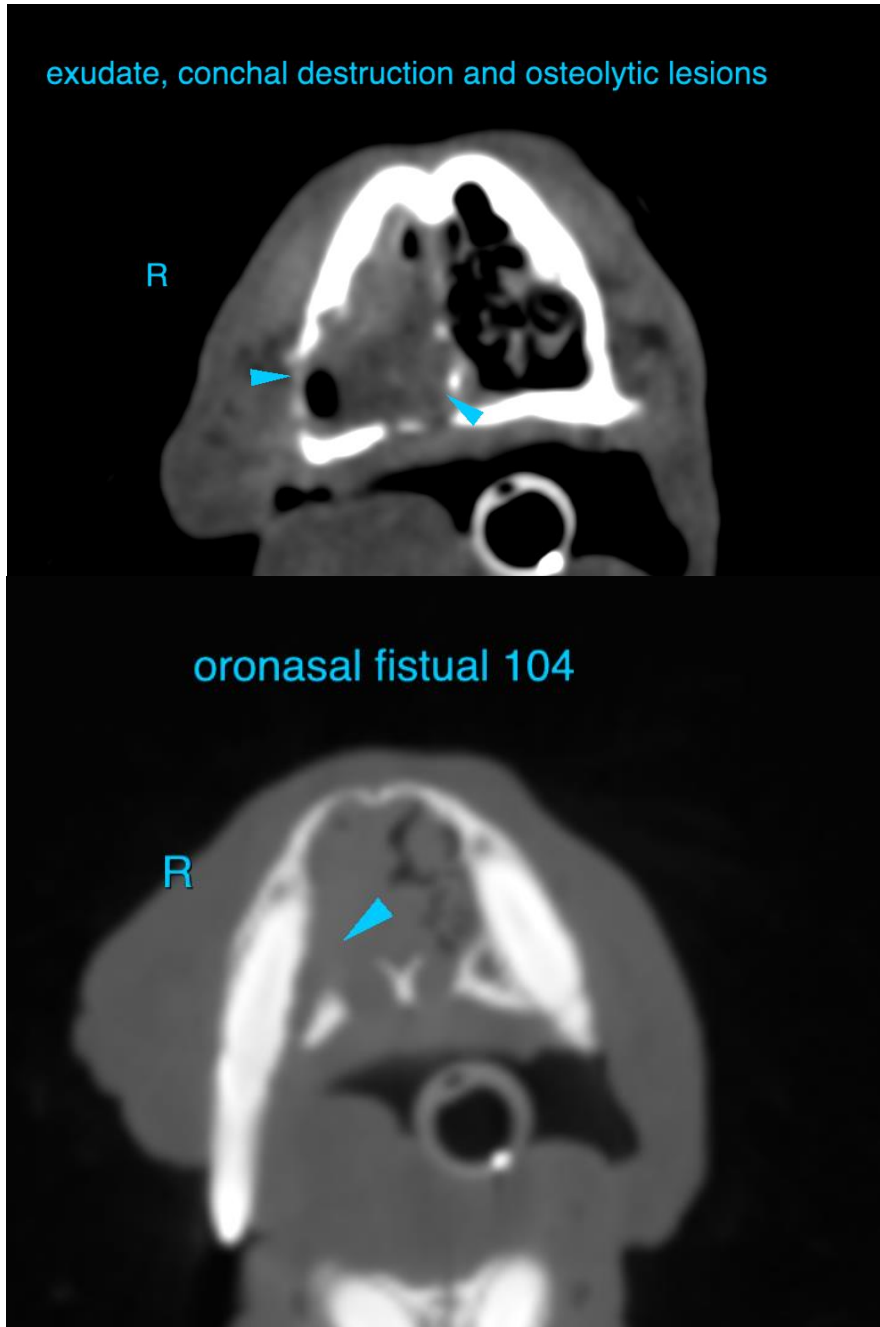
Borecky

INVOICE

52378

DATE

6-8-22





PATIENT

The information and recommendations provided are based on the images presented by the referring veterinarian/sonographer. No evaluation can be communicated regarding pathology that was not visible in the image/video clips provided.

Louie Gitter

SPECIES

Thank you for this referral. If the clinical or image interpretation does not parallel your findings or if I can be of any further assistance please contact me.

Canine

Sebastian Schaub, Sebastian Schaub, DVM, Dr. med. vet. DipECVDI
sebast.schaub@gmail.com

BREED

Maltese Mix

SEX

MN

AGE

13 Years

INTERPRETED BY

Sebastian Schaub, DVM
Dr. med. vet. DipECVDI

HOSPITAL NAME

Mobile Pet Imaging
CFL

REFERRING VET

Borecky

INVOICE

52378

DATE

6-8-22