



PATIENT

Deryck Copeland

PRESENTING CLINICAL SIGNS

09/05/2022: swelling under left eye ,not sure if tear ducts , fluo negative and not, passing to nose . teeth ok rest CE ok apart from bilateral entropion and lashes touching eye. 12/05/2022: Has a firm swelling at medial canthus of L eye (ongoing approx 1 week, acute presentation). Non painful on palp but nasal airflow reduced on this side and snotty discharge. 24/05/2022: OR lump on nose the same - no improvement with abs or NSAIDS. CT and biopsy today.

SPECIES

Feline

COMPUTED TOMOGRAPHY OF THE SKULL

A high resolution pre- and post-contrast CT study of the skull is provided for review.

BREED

Maine Coon

COMPUTED TOMOGRAPHIC FINDINGS

Triadan 201 is absent.

SEX

Male

Centered on the lateral and dorsal osseous lining of the left nasal cavity – the left nasal and maxillary bone – an expansile soft tissue attenuating and homogeneous mild to moderate contrast enhancing mass is appreciated. The left nasal mass is bulging into the subcutaneous tissue at the laterodorsal aspect of the nose and into the left nasal cavity. Moderate destruction of the left nasal conchal & turbinate structures is appreciated. The left nasal bone and left maxillary bone present permeative osteolytic lesions.

AGE

3 Years, 7 Months

Moderate hyperostosis of the osseous lining of the left frontal sinus is appreciated.

INTERPRETED BY

Sebastian Schaub, DVM
Dr. med. vet. DipECVDI

Both temporomandibular joints present congruent joint spaces with even subchondral bone surfaces and are considered within normal limits.

In both tympanic bullae, a mild amount of fluid attenuating material is attached to the osseous lining; the osseous lining of the tympanic bullae is mildly thickened and smooth.. The external ear canals are within normal limits.

HOSPITAL NAME

Animal Trust -
Ellesmere Port

The brain presents no deviation from normal anatomy and symmetry. The brain parenchyma is homogeneous and within normal limits for attenuation and distribution of contrast enhancement. The ventricular system is non-dilated and symmetric.

The tonsils are prominent.

REFERRING VET

Pippi Gould

The submandibular and medial retropharyngeal lymph nodes are significantly enlarged, rounded, uniform soft tissue attenuating and heterogeneous contrast enhancing.

COMPUTED TOMOGRAPHIC DIAGNOSIS

- Left sided biologically aggressive soft tissue mass centered on the osseous lining of the left nasal cavity
- Lymphadenopathy medial retropharyngeal and mandibular lymph nodes bilaterally
- Evidence of left sided chronic rhinosinusitis
- Bilateral mild otitis media
- Absent triadan 201

INVOICE

52364

DATE

6-8-22

INTERPRETATION OF THE FINDINGS & FURTHER RECOMMENDATIONS

The soft tissue mass on the left dorsolateral aspect of the left nasal cavity is highly suggestive for neoplastic disease, in combination with the enlarged tributary lymph nodes round cell neoplasia is considered as the top differential here. Theoretically granulomatous disease – e.g. due to



PATIENT

Deryck Copeland

mycotic rhinitis, Leishmaniasis – is a differential. If not done so yet, recommend FNA sampling of the swelling and the regional lymph nodes.

SPECIES

Feline

BREED

Maine Coon

SEX

Male

AGE

3 Years, 7 Months

INTERPRETED BY

Sebastian Schaub, DVM
Dr. med. vet. DipECVDI

HOSPITAL NAME

Animal Trust -
Ellesmere Port

REFERRING VET

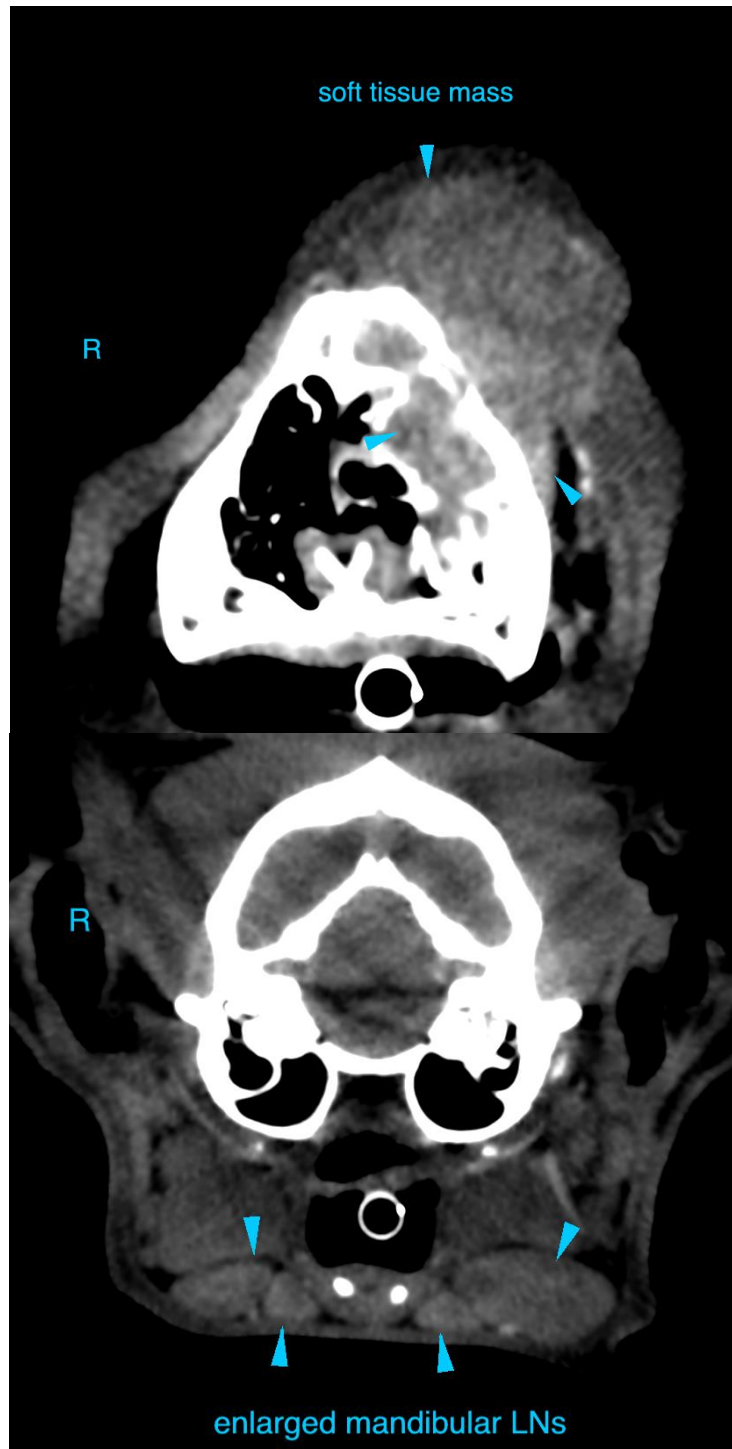
Pippi Gould

INVOICE

52364

DATE

6-8-22





PATIENT

Deryck Copeland

SPECIES

Feline

BREED

Maine Coon

SEX

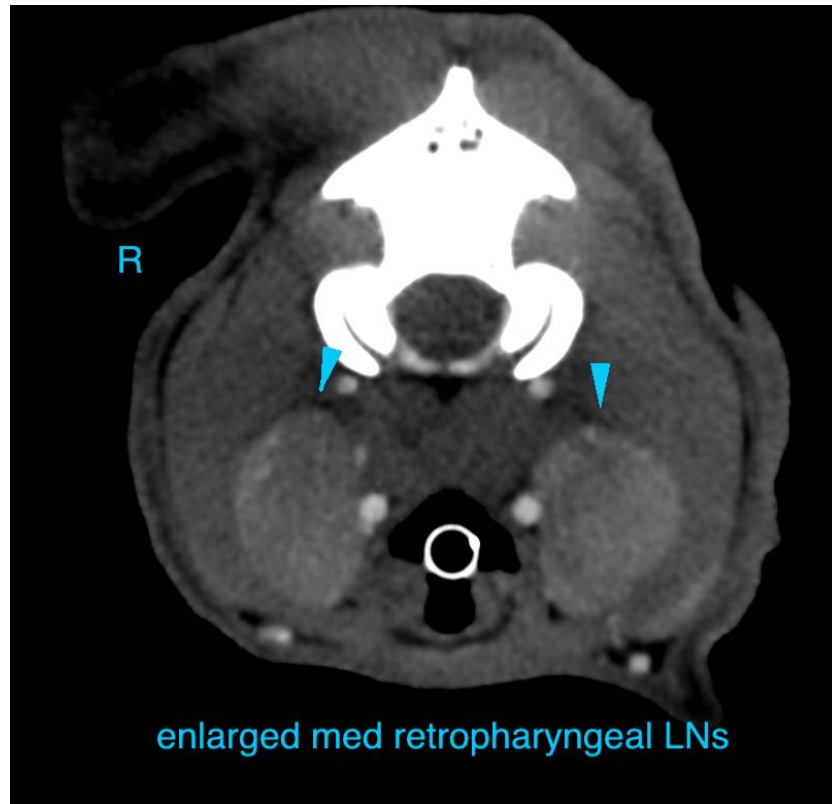
Male

AGE

3 Years, 7 Months

INTERPRETED BY

Sebastian Schaub, DVM
Dr. med. vet. DipECVDI



HOSPITAL NAME

Animal Trust -
Ellesmere Port

REFERRING VET

Pippi Gould

INVOICE

52364

DATE

6-8-22

The information and recommendations provided are based on the images presented by the referring veterinarian/sonographer. No evaluation can be communicated regarding pathology that was not visible in the image/video clips provided.

Thank you for this referral. If the clinical or image interpretation does not parallel your findings or if I can be of any further assistance please contact me.

Sebastian Schaub, Sebastian Schaub, DVM, Dr. med. vet. DipECVDI
sebast.schaub@gmail.com