



PATIENT

Bugsy Yurchuck

PRESENTING CLINICAL SIGNS

Patient came in after going through the garbage three days ago. Owner thinks that he ate paper and rotten meat. He did not eat for 3 days and only had a bowel movement once. He also threw up once yesterday. Wondering if there is a possibility of a foreign body in the X-rays.

SPECIES

Canine

RADIOGRAPHIC STUDY OF THE ABDOMEN

Radiographs of the abdomen in three imaging planes are provided for review. Radiographs are provided in JPEG file format.

BREED

Shih Poo Mix

RADIOGRAPHIC FINDINGS

The surrounding bony structures are within normal limits.

SEX

Neutered Male

No abnormalities of the extraabdominal soft tissues are noted. The abdominal wall is smooth and thin.

The serosal detail is maintained throughout the peritoneal and retroperitoneal space.

The liver is appropriate in position, size and presents uniform opacity.

AGE

9 Years

The splenic head is in the anticipated position and within normal limits for size and opacity. The splenic body and tail are considered normal for position, size, shape and opacity.

Both kidneys are seen and present with normal size, shape, delineation and opacity. The urinary bladder is in its anticipated position. No radiopaque calculi are noted throughout the upper and lower urinary tract.

INTERPRETED BY

Sebastian Schaub, DVM
Dr. med. vet. DipECVDI

The stomach is in its anticipated position and contains a mild to moderate amount of gas and foamy material.

The small intestinal loops are of even diameter and non-dilated, a small amount of gas is seen within the small intestinal loops and considered within normal limits.

HOSPITAL NAME

Wilson Road Vet
Clinic

The colon is seen in the expected position and contains a small amount of fecal material.

RADIOGRAPHIC DIAGNOSIS

- Foamy soft tissue material in stomach

REFERRING VET

Dr Ehab Yessa

INTERPRETATION OF THE FINDINGS & FURTHER RECOMMENDATIONS

The material in the stomach can indicate gastric emptying disorder, possibly due to gastritis or pancreatitis. However, some curled up foreign material (e.g. plastic foil) is a consideration. The intestinal tract presents without signs of mechanical obstruction. Basic blood work including cpl can be used to rule out pancreatitis. I would recommend empirical management for possible gastritis and reevaluating the patient – including follow up radiographs or an abdominal ultrasound examination – if clinical signs are refractory to therapy.

INVOICE

52363

DATE

6-8-22



PATIENT

Bugsy Yurchuck

SPECIES

Canine

BREED

Shih Poo Mix

SEX

Neutered Male

AGE

9 Years

INTERPRETED BY

Sebastian Schaub, DVM
Dr. med. vet. DipECVDI

HOSPITAL NAME

Wilson Road Vet
Clinic

REFERRING VET

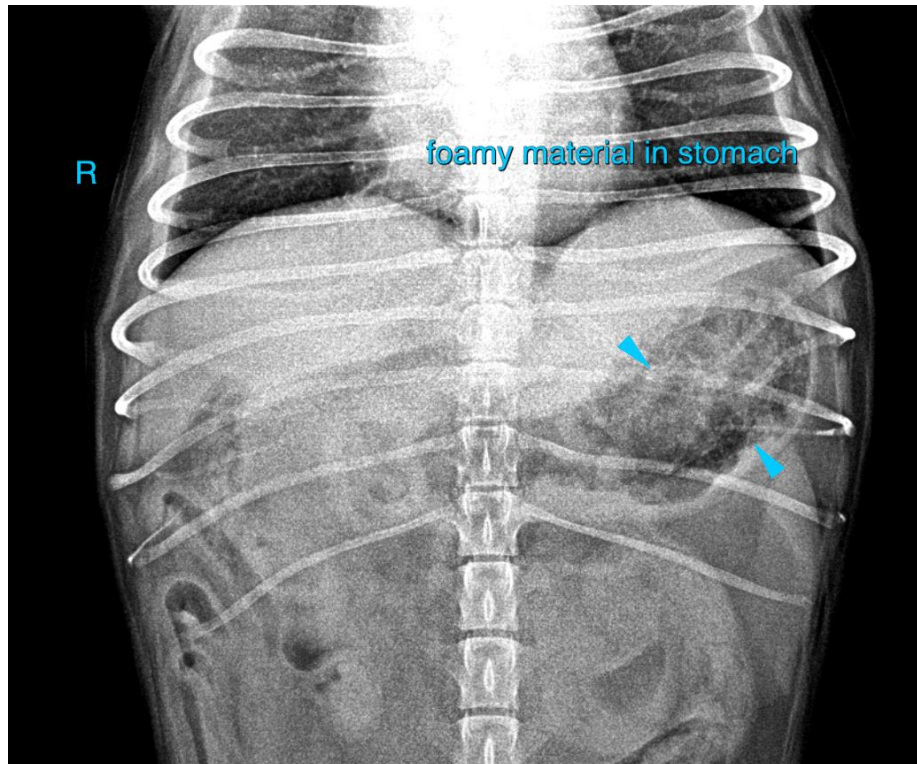
Dr Ehab Yessa

INVOICE

52363

DATE

6-8-22



The information and recommendations provided are based on the images presented by the referring veterinarian/sonographer. No evaluation can be communicated regarding pathology that was not visible in the image/video clips provided.

Thank you for this referral. If the clinical or image interpretation does not parallel your findings or if I can be of any further assistance please contact me.

Sebastian Schaub, Sebastian Schaub, DVM, Dr. med. vet. DipECVDI
sebast.schaub@gmail.com