



**PATIENT PRESENTING CLINICAL SIGNS**

Sadie Hartzler Pet presented to a local ER clinic 5 days ago after being hit in the head with a golf club. At presentation, the pet has bleeding from the nose and mouth (has since resolve, and the maxilla was visibly deviated. Skull films were taken that showed concern for bilateral maxillary fractures and the pet was referred for a CT scan. Pet has been on pain control and has been eating gruel and acting OK at home.

**SPECIES**

Canine Abnormal PE/Chem/CBC/UA Results: WNL

**COMPUTED TOMOGRAPHY OF THE SKULL**

**BREED**

A high resolution pre- and post-contrast CT study of the skull is provided for review.

Dachshund

**COMPUTED TOMOGRAPHIC FINDINGS**

The dentition is complete.

**SEX**

FS

Distal to the tooth roots of the maxillary canine teeth, a sharply delineated but irregular coursing transverse fracture line is running through the rostral segment of the nasal, maxillary and palatine bone bilaterally with mild to moderate right sided deviation & rotation of the rostral segment. A mild amount of fluid attenuating material is visible in the nasal cavity bilaterally, level with the fracture line. The palatine bone bilaterally presents with multiple fissure lines fracture line is running rostrally through the palatine bone, between triadan 202&203 - involving the alveolar crest of triadan 203.

**AGE**

4 Years, 8 Months

Both temporomandibular joints present congruent joint spaces with even subchondral bone surfaces and are considered within normal limits.

**INTERPRETED BY**

Sebastian Schaub, DVM  
Dr. med. vet. DipECVDI

Both tympanic bullae are aerated, the mucosal lining is not seen, the bony wall is smooth and thin. The external ear canals are within normal limits.

**HOSPITAL NAME**

Wilson Veterinary Hospital

The brain presents no deviation from normal anatomy and symmetry. The brain parenchyma is homogeneous and within normal limits for attenuation and distribution of contrast enhancement. The ventricular system is non-dilated and symmetric.

The submandibular and medial retropharyngeal lymph nodes are small and elongated with a normal short-to-long-axis-ratio is < 0.5, the attenuation and contrast enhancement pattern is uniform.

**REFERRING VET**

Outside clinic

**COMPUTED TOMOGRAPHIC DIAGNOSIS**

- History of craniomaxillofacial trauma with simple rostral midface fracture and right sided deviation and mild rotation of the rostral segment
- Fracture line involving the alveolar crest of triadan 203 and periapical segment of the alveolar crest of triadan 104&204
- Mild intranasal hematoma

**INVOICE**

52342

**INTERPRETATION OF THE FINDINGS & FURTHER RECOMMENDATIONS**

**DATE**

6-7-22

There is a simple rostral fracture of the midface with moderate right sided deviation and rotation of the separated rostral segment - including the nasal planum. Realigning and stabilization of the fracture using a splint system is considered feasible.



**PATIENT**

Sadie Hartzler

**SPECIES**

Canine

**BREED**

Dachshund

**SEX**

FS

**AGE**

4 Years, 8 Months

**INTERPRETED BY**

Sebastian Schaub, DVM  
Dr. med. vet. DipECVDI

**HOSPITAL NAME**

Wilson Veterinary  
Hospital

**REFERRING VET**

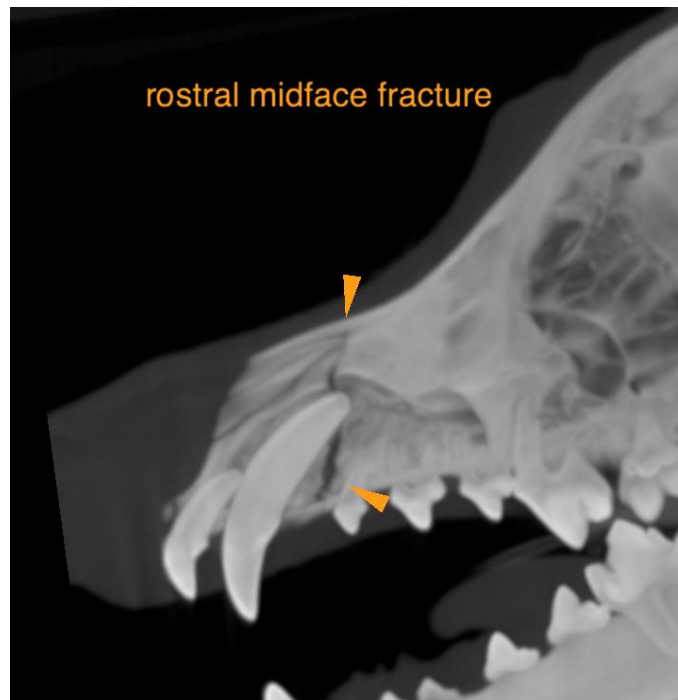
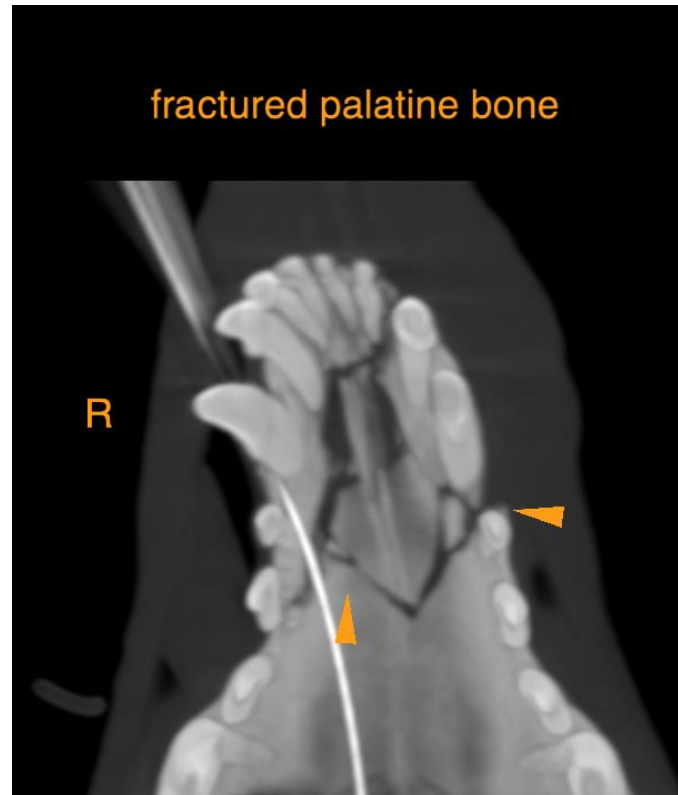
Outside clinic

**INVOICE**

52342

**DATE**

6-7-22





**PATIENT**

Sadie Hartzler

**SPECIES**

Canine

**BREED**

Dachshund

**SEX**

FS

**AGE**

4 Years, 8 Months

**INTERPRETED BY**

Sebastian Schaub, DVM  
Dr. med. vet. DipECVDI

**HOSPITAL NAME**

Wilson Veterinary  
Hospital

**REFERRING VET**

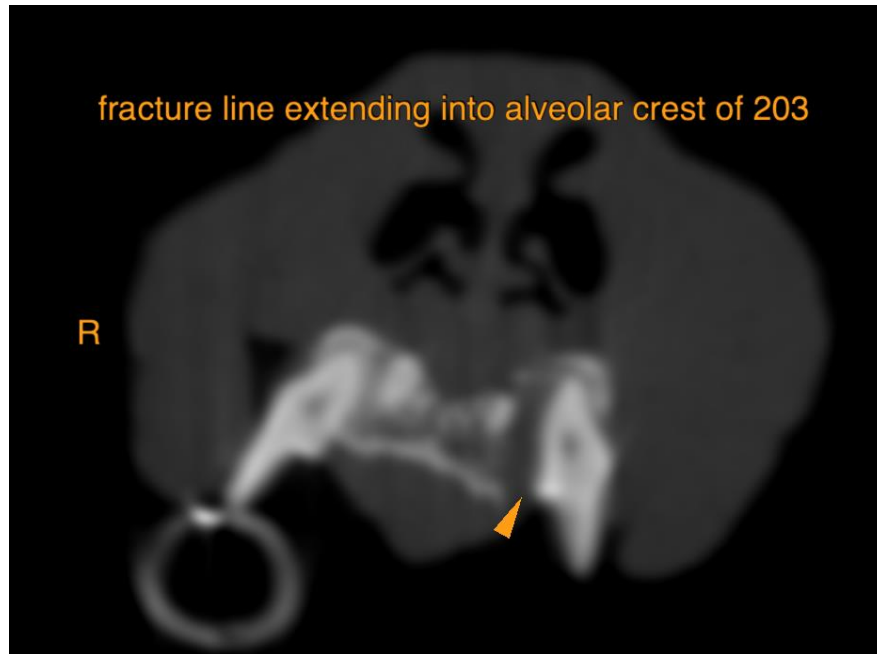
Outside clinic

**INVOICE**

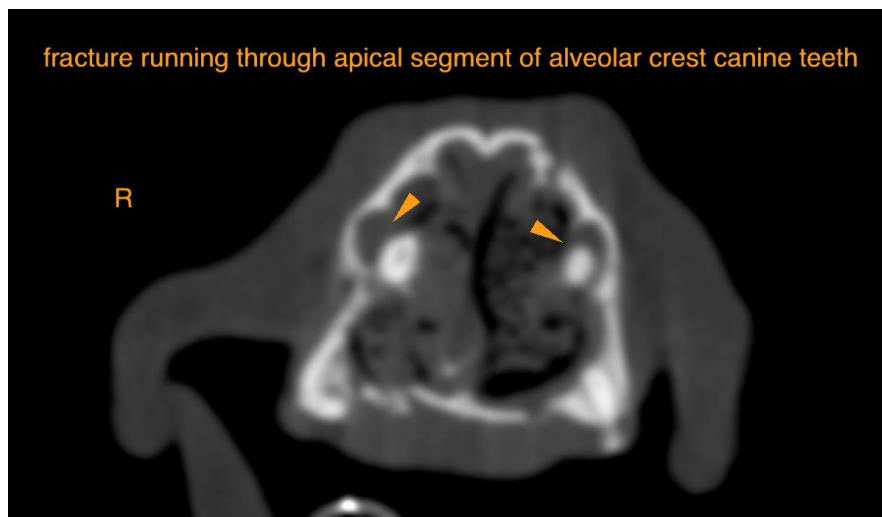52342

**DATE**

6-7-22



fracture line extending into alveolar crest of 203



fracture running through apical segment of alveolar crest canine teeth

The information and recommendations provided are based on the images presented by the referring veterinarian/sonographer. No evaluation can be communicated regarding pathology that was not visible in the image/video clips provided.

Thank you for this referral. If the clinical or image interpretation does not parallel your findings or if I can be of any further assistance please contact me.

**Sebastian Schaub**, Sebastian Schaub, DVM, Dr. med. vet. DipECVDI  
sebast.schaub@gmail.com