



PATIENT

Maddie Hart

PRESENTING CLINICAL SIGNS

P presented today for dental prophylaxis. New heart murmur (II-III/VI) noted that was not present 6 months ago. Labwork pending.

SPECIES

Canine

RADIOGRAPHIC STUDY OF THE THORAX

Radiographs of the thorax in three imaging planes are provided for review.

BREED

Chihuahua Mix

RADIOGRAPHIC FINDINGS

The intervertebral disc space T11/T12 is moderately narrowed and the respective vertebral endplates present mild spondylosis formation.

The extrathoracic soft tissues present homogeneous without abnormalities.

SEX

Female Spayed

The heart is of normal size and shape, there is no evidence of cardiac chamber or vascular enlargement. The vertebral heart score is 9.9. The pulmonary vasculature is within normal limits.

The cranial mediastinum presents the expected soft tissue opacity. The mediastinal width is less than twice the width of the vertebral column at the same level.

AGE

13.5 Years

The trachea is normal in diameter and presents the anticipated course. The luminal outline of the trachea is smooth.

The bronchial tree presents with thin walls and tapers uniformly towards the periphery as expected.

INTERPRETED BY

Sebastian Schaub, DVM
Dr. med. vet. DipECVDI

The lung parenchyma presents the expected architecture and opacity; the intrapulmonary vascular branching is seen up to the third order lung vessels.

The diaphragm is well delineated with even surface and the expected mild cranial bulging of the diaphragmatic cupola.

HOSPITAL NAME

All Creatures Animal
Hospital of South Hill,
Inc.

In the imaging plane of the renal pelvis bilaterally, mild to moderate mineralization is appreciated.

RADIOGRAPHIC DIAGNOSIS

- Bilateral nephrolithiasis
- Chronic discopathy T11/T12 with spondylosis formation
- Normal cardiac size

REFERRING VET

Amanda Hart

INTERPRETATION OF THE FINDINGS & FURTHER RECOMMENDATIONS

The cardiovascular structures present without radiographic abnormalities and a cardiac echo might be used for further workup of the appreciated heart murmur.

INVOICE

52341

DATE

6-7-22



PATIENT

Maddie Hart

SPECIES

Canine

BREED

Chihuahua Mix

SEX

Female Spayed

AGE

13.5 Years

INTERPRETED BY

Sebastian Schaub, DVM
Dr. med. vet. DipECVDI

HOSPITAL NAME

All Creatures Animal
Hospital of South Hill,
Inc.

REFERRING VET

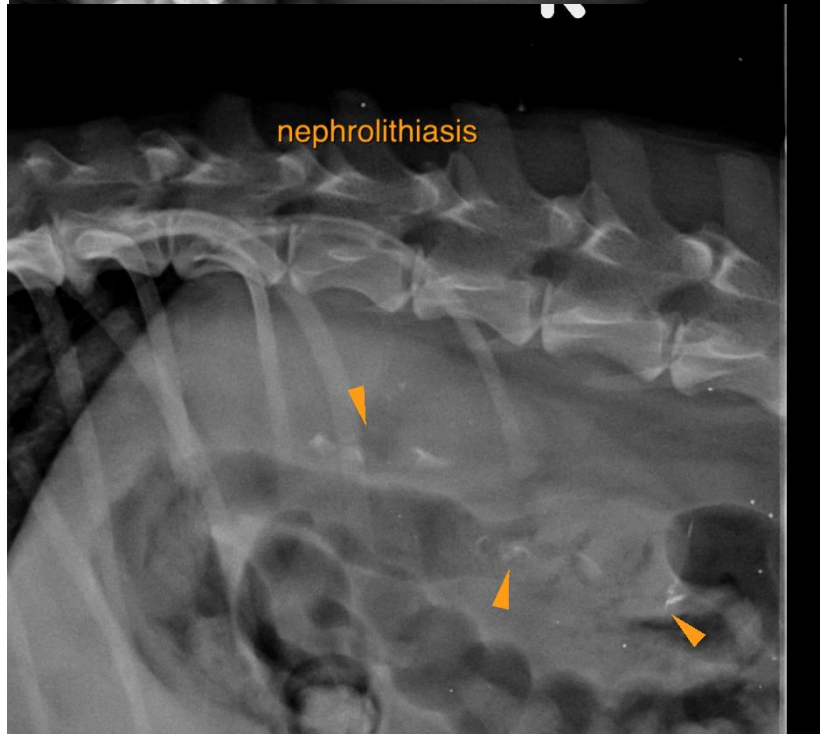
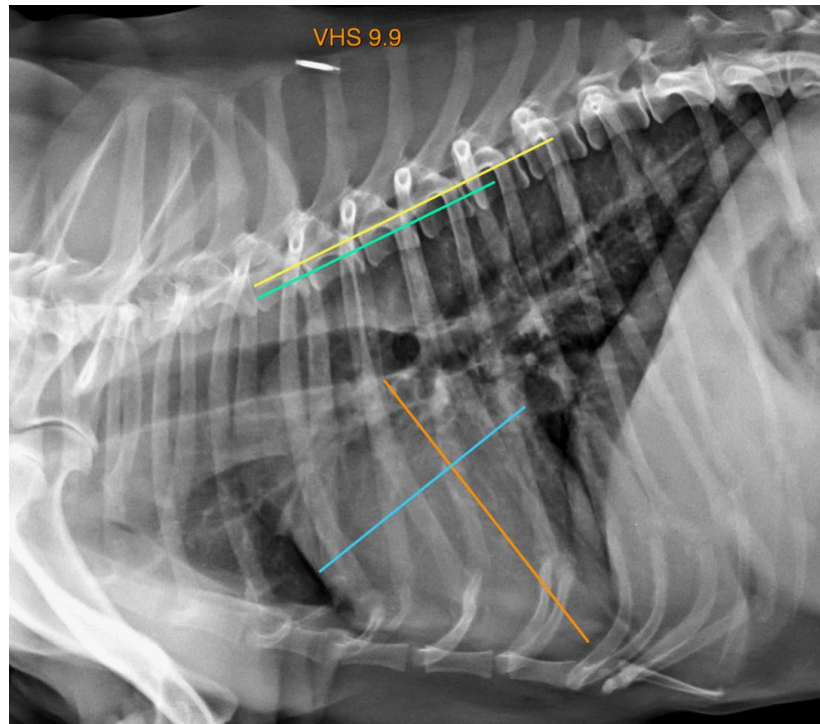
Amanda Hart

INVOICE

52341

DATE

6-7-22





PATIENT

Maddie Hart

The information and recommendations provided are based on the images presented by the referring veterinarian/sonographer. No evaluation can be communicated regarding pathology that was not visible in the image/video clips provided.

SPECIES

Canine

Thank you for this referral. If the clinical or image interpretation does not parallel your findings or if I can be of any further assistance please contact me.

BREED

Chihuahua Mix

Sebastian Schaub, Sebastian Schaub, DVM, Dr. med. vet. DipECVDI
sebast.schaub@gmail.com

SEX

Female Spayed

AGE

13.5 Years

INTERPRETED BY

Sebastian Schaub, DVM
Dr. med. vet. DipECVDI

HOSPITAL NAME

All Creatures Animal
Hospital of South Hill,
Inc.

REFERRING VET

Amanda Hart

INVOICE

52341

DATE

6-7-22