



PATIENT

Stella Hayes

PRESENTING CLINICAL SIGNS

Chronic ear infections. Has been getting amikacin injections since April. Right ear with purulent discharge today; was at groomer and missed last week's amikacin injection; suspect bulla issue as ear persists with discharge

SPECIES

K9

COMPUTED TOMOGRAPHY OF THE SKULL

A pre- and post-contrast CT study of the skull in a bone and soft tissue reconstruction is provided for review.

BREED

Goldendoodle

COMPUTED TOMOGRAPHIC FINDINGS

Triadan 201 presents a moderate widening of the periodontal space and resorptive lesions of the root.

SEX

Female Spayed

The nasal cavity presents the expected aerated spaces between thin & even conchae and turbinates with smooth mucosal lining.

AGE

10 Years

Both temporomandibular joints present congruent joint spaces with even subchondral bone surfaces and are considered within normal limits.

Both tympanic bullae are aerated, the mucosal lining is not seen, the bony wall is smooth and thin. The wall of the right external ear canal is moderately thickened.

INTERPRETED BY

Sebastian Schaub, DVM
Dr. med. vet. DipECVDI

The brain presents no deviation from normal anatomy and symmetry. The brain parenchyma is homogeneous and within normal limits for attenuation and distribution of contrast enhancement. The ventricular system is non-dilated and symmetric.

The submandibular and medial retropharyngeal lymph nodes are small and elongated with a normal short-to-long-axis-ratio is < 0.5, the attenuation and contrast enhancement pattern is uniform.

HOSPITAL NAME

Westwood Regional
Veterinary Hospital

COMPUTED TOMOGRAPHIC DIAGNOSIS

- History of otitis externa, R>L
- Periodontal disease 201 with tooth root resorption
- No evidence of otitis media or interna

REFERRING VET

Goldman

INTERPRETATION OF THE FINDINGS & FURTHER RECOMMENDATIONS

The CT study is fitting the history of otitis externa. No underlying cause for the otitis externa is appreciated. There are no signs for accompanying otitis media.

INVOICE

52313

DATE

6-6-22



PATIENT

Stella Hayes

SPECIES

K9

BREED

Goldendoodle

SEX

Female Spayed

AGE

10 Years

INTERPRETED BY

Sebastian Schaub, DVM
Dr. med. vet. DipECVDI

HOSPITAL NAME

Westwood Regional
Veterinary Hospital

REFERRING VET

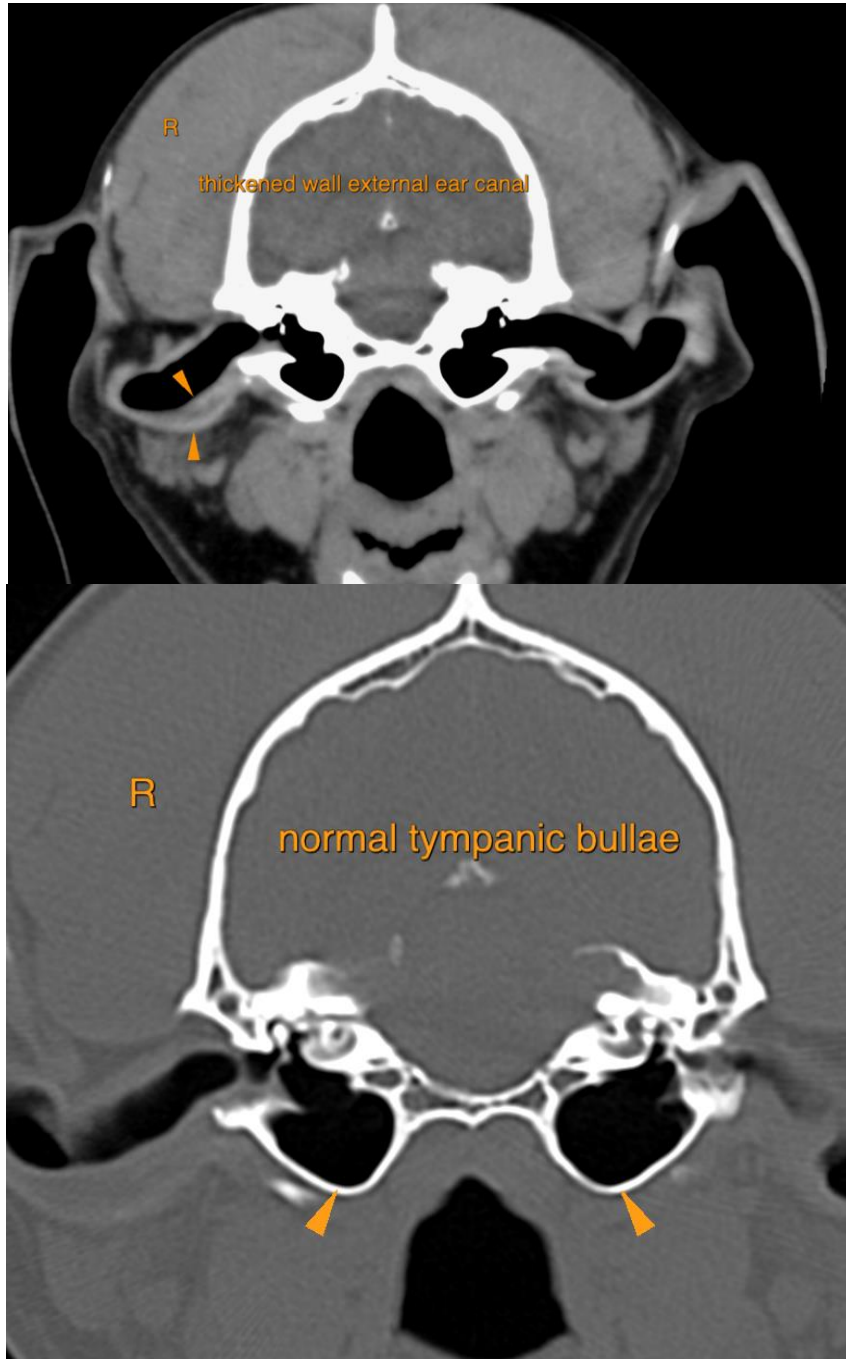
Goldman

INVOICE

52313

DATE

6-6-22





PATIENT

Stella Hayes

SPECIES

K9

BREED

Goldendoodle

SEX

Female Spayed

AGE

10 Years

INTERPRETED BY

Sebastian Schaub, DVM
Dr. med. vet. DipECVDI

HOSPITAL NAME

Westwood Regional
Veterinary Hospital

REFERRING VET

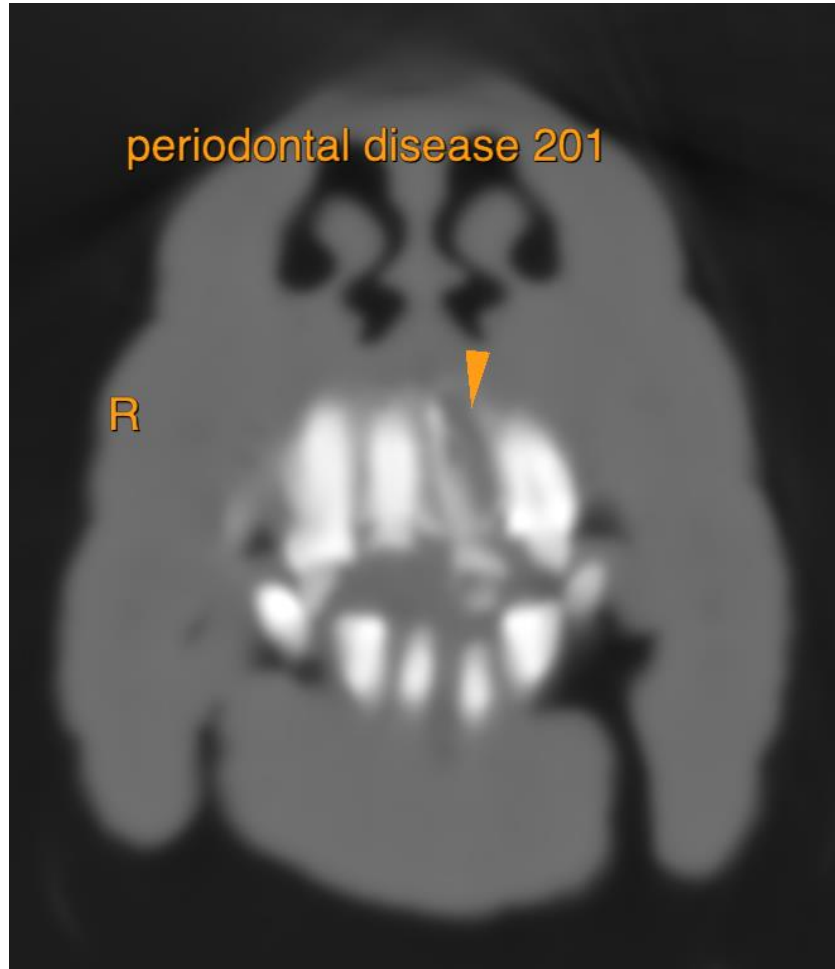
Goldman

INVOICE

52313

DATE

6-6-22



The information and recommendations provided are based on the images presented by the referring veterinarian/sonographer. No evaluation can be communicated regarding pathology that was not visible in the image/video clips provided.

Thank you for this referral. If the clinical or image interpretation does not parallel your findings or if I can be of any further assistance please contact me.

Sebastian Schaub, Sebastian Schaub, DVM, Dr. med. vet. DipECVDI
sebast.schaub@gmail.com