



PATIENT PRESENTING CLINICAL SIGNS

Murohy Zamora
SPECIES Canine
BREED Goldendoodle
 Murphy keeps throwing up. It has been going on for about a 1.5 weeks. When it first started, she noticed pieces of what looked like plastic zipties. The vomiting tends to happen after he drinks water. It doesn't matter if he drinks fast or slow. There is no retching. Murphy is eating Science Diet, but was on Blue Buffalo 4 weeks ago. He doesn't vomit if he eats but will vomit if he eats food and then drinks water. His appetite is decreased and he doesn't seem interested in his food. The vomit looks like bile and foam.
 Abnormal PE/Chem/CBC/UA Results: BAR, EENT normal, abdomen palpates normally with no pain or abnormalities. Heart/lungs normal. Ambulatory x4 with normal gait.

RADIOGRAPHIC STUDY OF THE NECK, THORAX AND ABDOMEN

A complete set of radiographs of the neck, thorax and abdomen is provided for review.

RADIOGRAPHIC FINDINGS

SEX Neck

Male The osseous structures of the neck are within normal limits.

The cranial esophageal segment is mildly distended by gas, mildly accentuating the cranial esophageal sphincter.

AGE Thorax

1 Year, 3 Months The surrounding bony structures are within normal limits.

INTERPRETED BY The extrathoracic soft tissues present homogeneous without abnormalities.

Sebastian Schaub, DVM
 Dr. med. vet. DipECVDI The heart is of normal size and shape, there is no evidence of cardiac chamber or vascular enlargement. The pulmonary vasculature is within normal limits.

HOSPITAL NAME The cranial mediastinum presents the expected soft tissue opacity. The mediastinal width is less than twice the width of the vertebral column at the same level.

Elizabeth Animal Hospital The trachea is normal in diameter and presents the anticipated course. The luminal outline of the trachea is smooth.

REFERRING VET The bronchial tree presents with thin walls and tapers uniformly towards the periphery as expected.

Leon Anderson, DVM The lung parenchyma presents the expected architecture and opacity; the intrapulmonary vascular branching is seen up to the third order lung vessels.

INVOICE The diaphragm is well delineated with even surface and the expected mild cranial bulging of the diaphragmatic cupola.

52312 Abdomen

The surrounding bony structures are within normal limits.

DATE No abnormalities of the extraabdominal soft tissues are noted. The abdominal wall is smooth and thin.

6-6-22 The serosal detail is maintained throughout the peritoneal and retroperitoneal space.



PATIENT

Murohy Zamora

The liver is appropriate in position, size and presents uniform opacity.

The splenic head is in the anticipated position and within normal limits for size and opacity. The splenic body and tail are considered normal for position, size, shape and opacity.

SPECIES

Canine

Both kidneys are seen and present with normal size, shape, delineation and opacity. The urinary bladder is in its anticipated position. No radiopaque calculi are noted throughout the upper and lower urinary tract.

BREED

Goldendoodle

The stomach is in its anticipated position and contains a mild amount of fluid & foamy material

The small intestinal loops are of even diameter and non-dilated, a small amount of gas is seen within the small intestinal loops and considered within normal limits.

The colon is seen in the expected position and presents with appropriate content.

SEX

Male

- Mild fluid filled stomach
- Normal thorax
- Normal neck

AGE

1 Year, 3 Months

INTERPRETED BY

Sebastian Schaub, DVM
Dr. med. vet. DipECVDI

INTERPRETATION OF THE FINDINGS & FURTHER RECOMMENDATIONS

The mild fluid filled stomach is not specific but can indicate gastritis ± gastric emptying disorder. There is no evidence of radiopaque foreign material. If clinical signs are refractory to empirical therapy, recommend follow up radiographs or a complete abdominal ultrasound examination; in some cases, a high ileus may lack classical radiographic signs of mechanical obstruction – appears unlikely due to respective clinical signs.

HOSPITAL NAME

Elizabeth Animal
Hospital

REFERRING VET

Leon Anderson, DVM

INVOICE

52312

DATE

6-6-22



PATIENT

Murohy Zamora

SPECIES

Canine

BREED

Goldendoodle

SEX

Male

AGE

1 Year, 3 Months

INTERPRETED BY

Sebastian Schaub, DVM
Dr. med. vet. DipECVDI

HOSPITAL NAME

Elizabeth Animal
Hospital

REFERRING VET

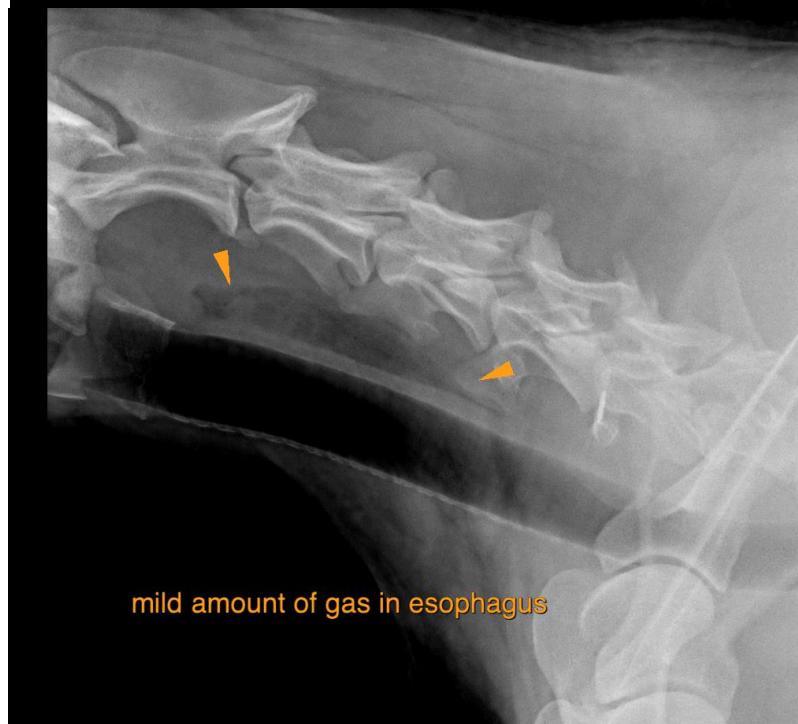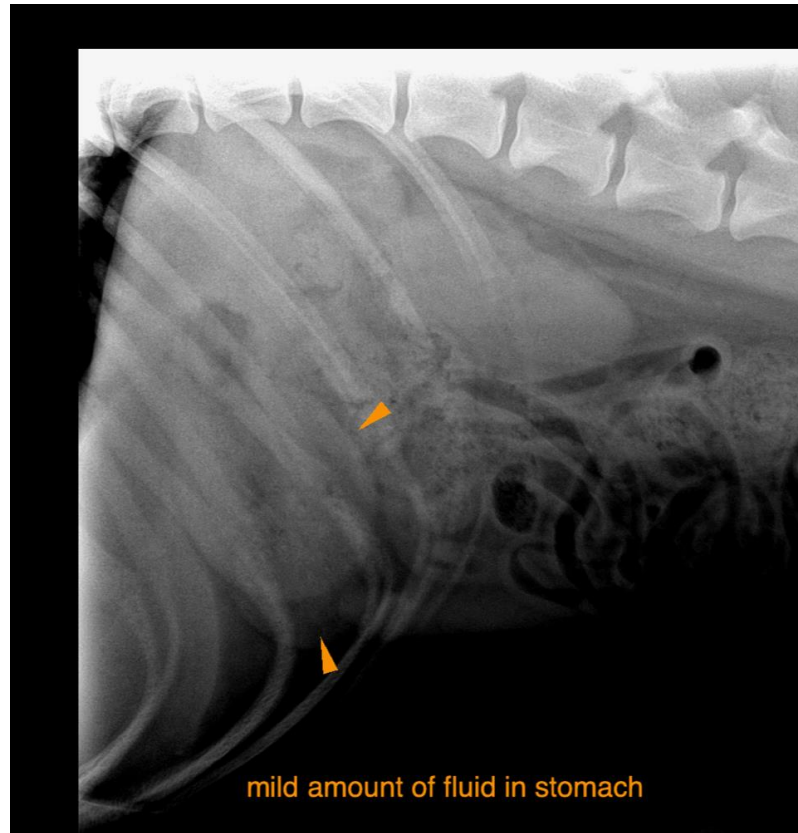
Leon Anderson, DVM

INVOICE

52312

DATE

6-6-22





PATIENT

Murohy Zamora

SPECIES

Canine

The information and recommendations provided are based on the images presented by the referring veterinarian/sonographer. No evaluation can be communicated regarding pathology that was not visible in the image/video clips provided.

BREED

Goldendoodle

Thank you for this referral. If the clinical or image interpretation does not parallel your findings or if I can be of any further assistance please contact me.

Sebastian Schaub, Sebastian Schaub, DVM, Dr. med. vet. DipECVDI
sebast.schaub@gmail.com

SEX

Male

AGE

1 Year, 3 Months

INTERPRETED BY

Sebastian Schaub, DVM
Dr. med. vet. DipECVDI

HOSPITAL NAME

Elizabeth Animal
Hospital

REFERRING VET

Leon Anderson, DVM

INVOICE

52312

DATE

6-6-22