



PATIENT

Autumn McDaniel

SPECIES

Feline

BREED

DSH

SEX

Spayed Female

AGE

10 Years 6 Months

WEIGHT

10.12 Pounds

INTERPRETED BY

Sebastian Schaub, DVM
Dr. med. vet. DipECVDI

IMAGING PERFORMED BY

Ashlyn Colapietro

HOSPITAL NAME

Queen Creek VC

REFERRING VET

Dr. Brendan Walker

INVOICE

37288

DATE

6/5/26

PRESENTING CLINICAL SIGNS

History: Presented to GQ ER for oral pain and bleeding post-dental. Was also experiencing inappetence and lethargy. DVM noted significant gingival reaction in upper right arcade, and 108 was extracted. Got Convenia and Depomedrol on 5/25 at ER. Unable to give Gabapentin orally.

COMPUTED TOMOGRAPHIC STUDY OF THE SKULL

A high resolution pre- and post-contrast CT study of the skull is provided for review.

COMPUTED TOMOGRAPHIC FINDINGS

The tooth elements 101-103, 107, 108, 201, 207, 209, 301-303, 307, 309 are absent.

The nasal cavity presents the expected aerated spaces between thin & even conchae and turbinates with smooth mucosal lining.

Both temporomandibular joints present congruent joint spaces with even subchondral bone surfaces and are considered within normal limits.

Both tympanic bullae are aerated, the mucosal lining is not seen, the bony wall is smooth and thin. The external ear canals are within normal limits.

The brain presents no deviation from normal anatomy and symmetry. The brain parenchyma is homogeneous and within normal limits for attenuation and distribution of contrast enhancement. The ventricular system is non-dilated and symmetric.

The submandibular and medial retropharyngeal lymph nodes are small and elongated with a normal short-to-long-axis-ratio is < 0.5, the attenuation and contrast enhancement pattern is uniform.

COMPUTED TOMOGRAPHIC DIAGNOSIS

- History of dental extraction
- Ankylosis and resorptive lesions 104

INTERPRETATION OF THE FINDINGS & FURTHER RECOMMENDATIONS

The CT study reveals no abnormalities, that do explain the described clinical signs – rule out feline orofacial pain syndrome as potential differential as well.



PATIENT

Autumn McDaniel

SPECIES

Feline

BREED

DSH

SEX

Spayed Female

AGE

10 Years 6 Months

WEIGHT

10.12 Pounds

INTERPRETED BY

Sebastian Schaub, DVM
Dr. med. vet. DipECVDI

IMAGING PERFORMED BY

Ashlyn Colapietro

HOSPITAL NAME

Queen Creek VC

REFERRING VET

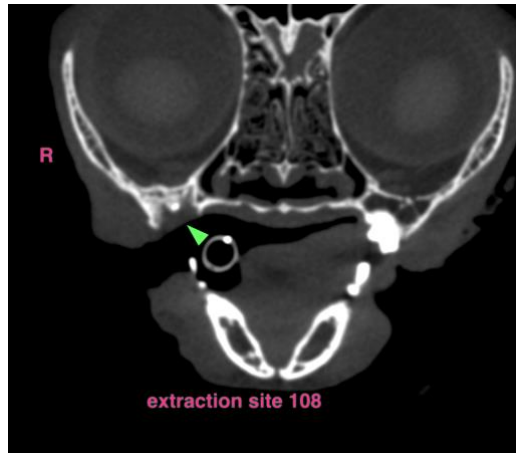
Dr. Brendan Walker

INVOICE

37288

DATE

6/5/26



The information and recommendations provided are based on the images presented by the referring veterinarian/sonographer. No evaluation can be communicated regarding pathology that was not visible in the image/video clips provided.

Thank you for this referral. If the clinical or image interpretation does not parallel your findings or if I can be of any further assistance please contact me.

Sebastian Schaub, DVM, Dr. med. vet. DipECVDI
info@sonopath.com