



PATIENT

Birdie Animals in
Distress

SPECIES

Feline

BREED

Domestic Shorthair

SEX

Spayed Female

AGE

6Y, 11M

WEIGHT

14.02lbs

INTERPRETED BY

Sebastian Schaub, DVM
Dr. med. vet.
DipECVDI

IMAGING PERFORMED BY

Renee Ziegler Post

HOSPITAL NAME

For Cats Only
Veterinary Clinic

REFERRING VET

Renee Ziegler Post

INVOICE

75316

DATE

6-4-26

PRESENTING CLINICAL SIGNS

Presented May 20th with moist, phlegmy sounding cough. Comparison radiographs from 5/20/26 and today 6/4/26

RADIOGRAPHIC STUDY OF THE THORAX

Radiographs of the thorax in two imaging planes are provided for review.

RADIOGRAPHIC FINDINGS

Thorax 5/20/26

The body condition score is 8/9.

The surrounding bony structures are within normal limits.

The extrathoracic soft tissues present homogeneous without abnormalities.

The heart is of normal size and shape; there is no evidence of cardiac chamber or vascular enlargement. The pulmonary vasculature is within normal limits.

The mediastinum is widened by fat.

The trachea is normal in diameter and presents the anticipated course. The luminal outline of the trachea is smooth.

The bronchial walls are prominent.

The lung parenchyma presents the expected architecture and opacity; the intrapulmonary vascular branching is seen up to the third order lung vessels.

The diaphragm is well delineated with even surface and the expected mild cranial bulging of the diaphragmatic cupola.

Thorax 6/4/26

In comparison to the preceding radiographic study, the bronchial pattern is regressive.

No additional findings.

RADIOGRAPHIC DIAGNOSIS

- Bronchial lung pattern, in remission in the follow up radiographs – no evidence of air-trapping
- Obesity

INTERPRETATION OF THE FINDINGS & FURTHER RECOMMENDATIONS

The bronchial lung pattern is suggestive for bronchitis either due to feline bronchial disease ± bacterial or viral superinfection or due to primary infectious bronchitis – the findings are regressive in the follow up radiographs of the thorax.



PATIENT

Birdie Animals in
Distress

SPECIES

Feline

BREED

Domestic Shorthair

SEX

Spayed Female

AGE

6Y, 11M

WEIGHT

14.02lbs

INTERPRETED BY

Sebastian Schaub, DVM
Dr. med. vet.
DipECVDI

IMAGING PERFORMED BY

Renee Ziegler Post

HOSPITAL NAME

For Cats Only
Veterinary Clinic

REFERRING VET

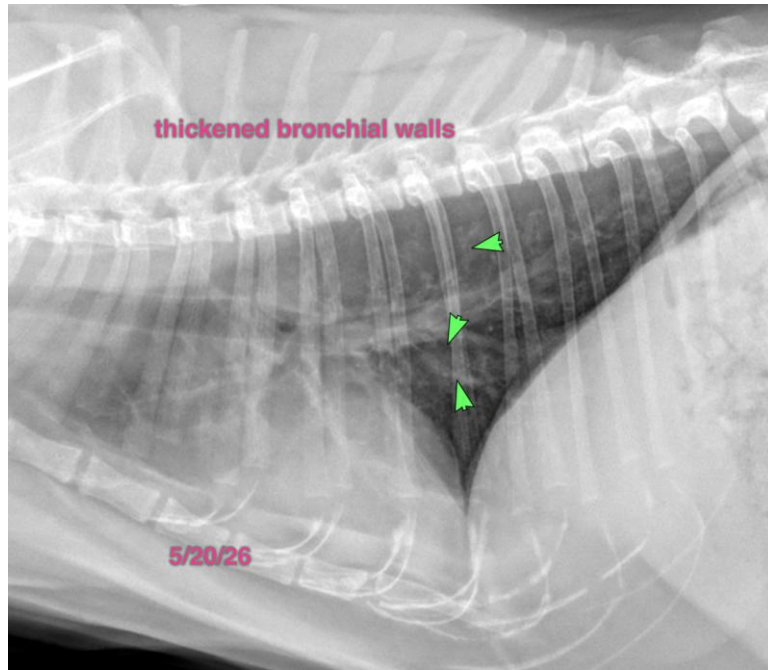
Renee Ziegler Post

INVOICE

75316

DATE

6-4-26



The information and recommendations provided are based on the images presented by the referring veterinarian/sonographer. No evaluation can be communicated regarding pathology that was not visible in the image/video clips provided.

Thank you for this referral. If the clinical or image interpretation does not parallel your findings or if I can be of any further assistance please contact me.

Sebastian Schaub, Sebastian Schaub, DVM, Dr. med. vet. DipECVDI
info@sonopath.com