



**PATIENT**

Benjamin Salter

**PRESENTING CLINICAL SIGNS**

sudden onset of swelling in left front leg. was presented with non-weight bearing on LF . has fever  
Abnormal PE/Chem/CBC/UA Results: elevated WBCs

**SPECIES**

Canine

**RADIOGRAPHIC STUDY OF THE LEFT ELBOW JOINT**

Radiographs of the left elbow joint in two orthogonal imaging planes are provided for review.

**BREED**

Mastiff

**RADIOGRAPHIC FINDINGS**

At the caudal aspect of the left elbow joint and the caudal aspect of the left antebrachium, a homogeneous, diffuse, moderate to marked soft tissue swelling is appreciated. The osseous structures of the left elbow joint present smooth osseous margins. Very small mineralizations are seen proximal to the olecranon.

**SEX**

Male

**RADIOGRAPHIC DIAGNOSIS**

- Diffuse soft tissue swelling caudal aspect of the left elbow joint and antebrachium
- Small mineralized bodies proximal to left olecranon

**AGE**

9 Months

**INTERPRETATION OF THE FINDINGS & FURTHER RECOMMENDATIONS**

The soft tissue swelling of the distal aspect of the left front limb in combination with the fever and leukocytosis is highly suggestive for inflammatory origin – such as abscess formation or phlegmon. Other potentials include bug bite, edema or hematoma. An ultrasound examination of the swelling can be used to screen for fluid accumulation, warranting surgical drainage.

**INTERPRETED BY**

Sebastian Schaub, DVM  
Dr. med. vet. DipECVDI

The small mineralization proximal to the left olecranon might indicate mild enthesophyte formation, anyway ultrasound can be used to check normal integrity of the tendon of the triceps muscle.

**HOSPITAL NAME**

St. Catherine's Animal  
Hospital

**REFERRING VET**

Dr. Boctor

**INVOICE**

52300

**DATE**

6-4-22



**PATIENT**

Benjamin Salter

**SPECIES**

Canine

**BREED**

Mastiff

**SEX**

Male

**AGE**

9 Months

**INTERPRETED BY**

Sebastian Schaub, DVM  
Dr. med. vet. DipECVDI

**HOSPITAL NAME**

St. Catherine's Animal  
Hospital

**REFERRING VET**

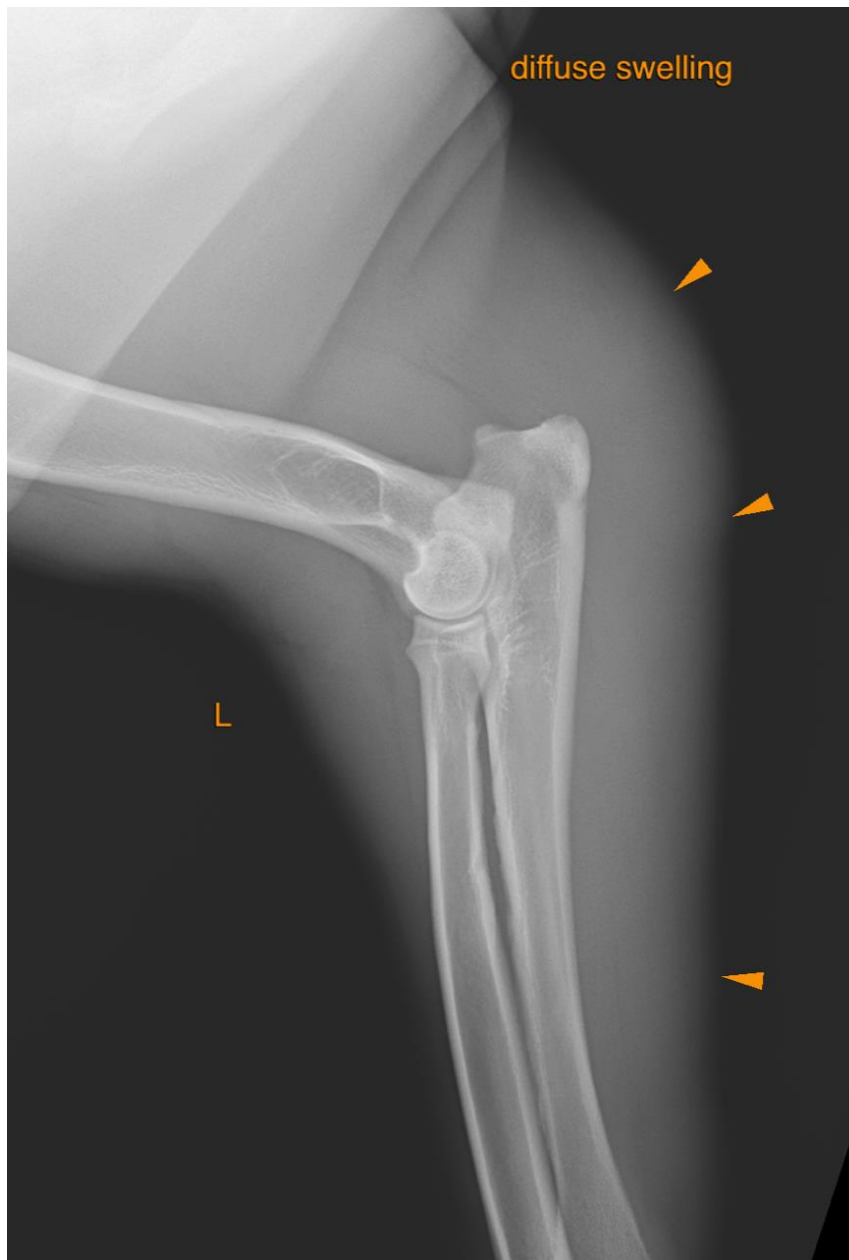
Dr. Boctor

**INVOICE**

52300

**DATE**

6-4-22





**PATIENT**

Benjamin Salter

**SPECIES**

Canine

**BREED**

Mastiff

**SEX**

Male

**AGE**

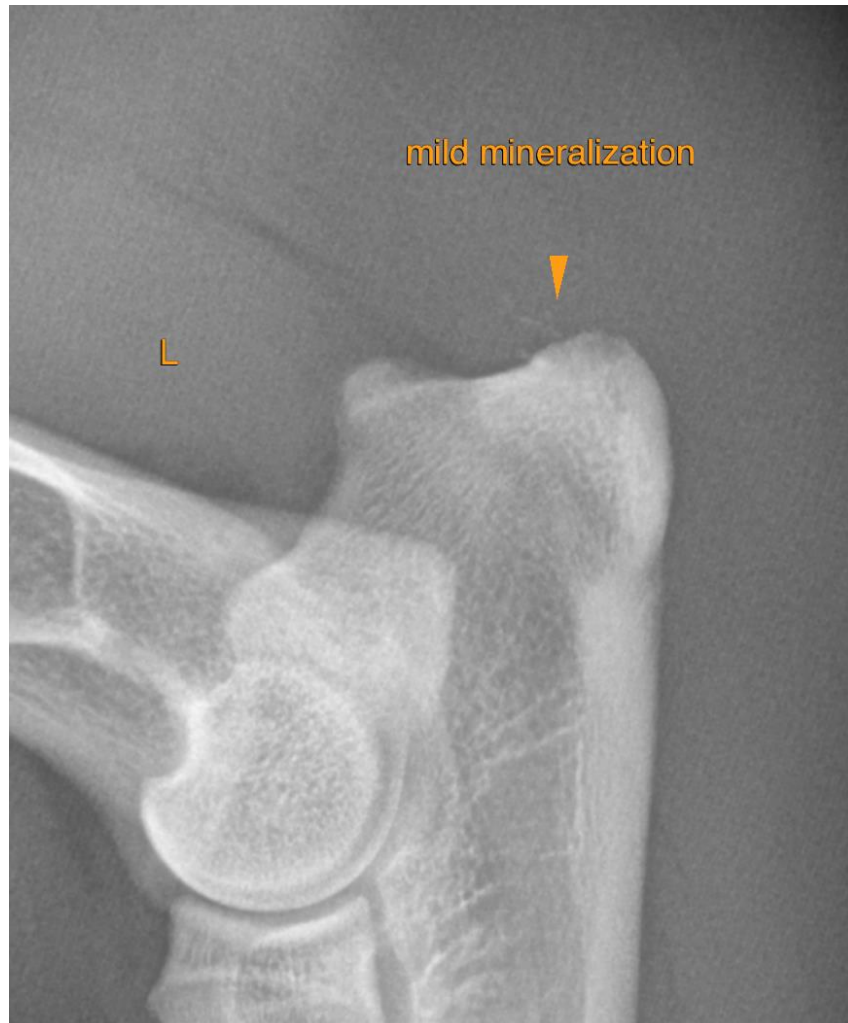9 Months

**INTERPRETED BY**

Sebastian Schaub, DVM  
Dr. med. vet. DipECVDI

**HOSPITAL NAME**

St. Catherine's Animal  
Hospital



**REFERRING VET**

Dr. Boctor

**INVOICE**

52300

**DATE**

6-4-22

The information and recommendations provided are based on the images presented by the referring veterinarian/sonographer. No evaluation can be communicated regarding pathology that was not visible in the image/video clips provided.

Thank you for this referral. If the clinical or image interpretation does not parallel your findings or if I can be of any further assistance please contact me.

**Sebastian Schaub**, Sebastian Schaub, DVM, Dr. med. vet. DipECVDI  
sebast.schaub@gmail.com