



PATIENT PRESENTING CLINICAL SIGNS

Benny Norberto Ongoing history of nasal congestion for several years. Previously biopsies with inflammatory changes. Sneezing, discharge and occasional dry cough ongoing.

SPECIES COMPUTED TOMOGRAPHY OF THE SKULL

Canine A high resolution pre- and post-contrast CT study of the is provided for review.

COMPUTED TOMOGRAPHIC FINDINGS

BREED A mild bradygnathia superior is appreciated. The tooth elements 311 & 411 are absent.

Shih Tzu In the caudodorsal aspect of the left nasal cavity, a moderate amount of fluid attenuating material is attached to the nasal mucosal lining. The nasal cavity presents the expected aerated spaces between thin & even conchae and turbinates with smooth mucosal lining.

SEX Both temporomandibular joints present congruent joint spaces with even subchondral bone surfaces and are considered within normal limits.

MC Both tympanic bullae are aerated, the mucosal lining is not seen, the bony wall is smooth and thin. The external ear canals are within normal limits.

AGE The brain presents no deviation from normal anatomy and symmetry. The brain parenchyma is homogeneous and within normal limits for attenuation and distribution of contrast enhancement. The ventricular system is non-dilated and symmetric.

8 Years

INTERPRETED BY The submandibular and medial retropharyngeal lymph nodes are small and elongated with a normal short-to-long-axis-ratio is < 0.5, the attenuation and contrast enhancement pattern is uniform.

Sebastian Schaub, DVM
Dr. med. vet. DipECVDI

COMPUTED TOMOGRAPHIC DIAGNOSIS

- Rhinitis, L>R
- Absent triadan 311 & 411

HOSPITAL NAME

Pet Emergency &
Referral Center - NVA

INTERPRETATION OF THE FINDINGS & FURTHER RECOMMENDATIONS

The computed tomographic findings are suggestive for non-specific rhinitis (e.g. lymphocytic plasmocytic, eosinophilic) ± bacterial superinfection. Repeating rhinoscopy including sampling for histopathology and microbial might be used as advanced diagnostic tests and to rule out underlying nasal mites.

REFERRING VET

Dr. Elizabeth Lechner

INVOICE

59107

DATE

6-30-23



PATIENT

Benny Norberto

SPECIES

Canine

BREED

Shih Tzu

SEX

MC

AGE

8 Years

INTERPRETED BY

Sebastian Schaub, DVM
Dr. med. vet. DipECVDI

HOSPITAL NAME

Pet Emergency &
Referral Center - NVA

REFERRING VET

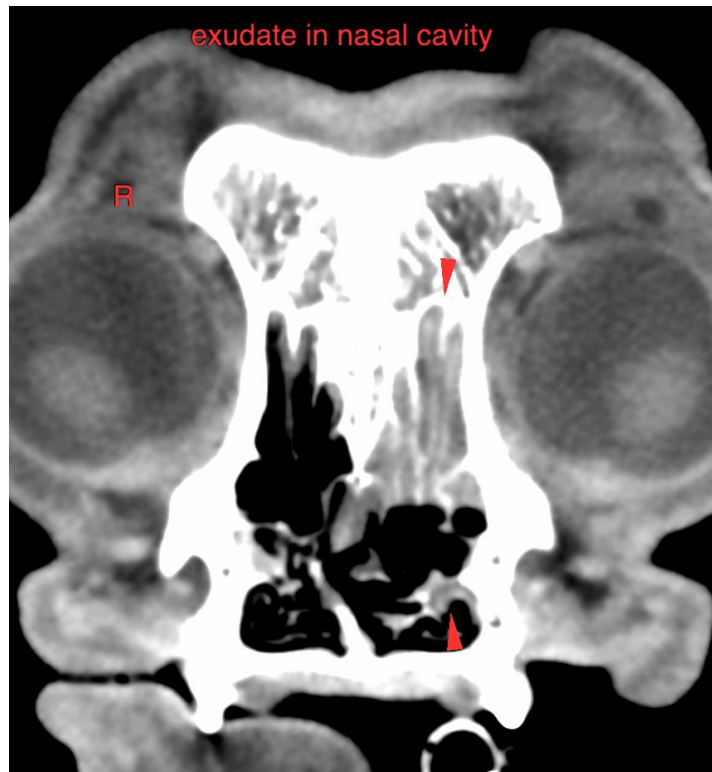
Dr. Elizabeth Lechner

INVOICE

59107

DATE

6-30-23



The information and recommendations provided are based on the images presented by the referring veterinarian/sonographer. No evaluation can be communicated regarding pathology that was not visible in the image/video clips provided.

Thank you for this referral. If the clinical or image interpretation does not parallel your findings or if I can be of any further assistance please contact me.

Sebastian Schaub, Sebastian Schaub, DVM, Dr. med. vet. DipECVDI
info@sonopath.com