



PATIENT

Zoey Huntsman

PRESENTING CLINICAL SIGNS

O got home around 7:45pm Tuesday and Zoey seemed fine. They went outside for a bit and O noticed Zoey kept turning to the side like she was hurting. O then noticed her L eye was swollen and almost shut. It is watering a bit as well. Since then, it seems to have gone down below her eye and to the top of her nose as well. O wonders if she got bitten by something. O tried to give an allergy medication but she wouldn't take it even though she usually takes things in treats well. Abnormal PE/Chem/CBC/UA Results: Exophthalmos OS with periorbital swelling, mild mucoid discharge OS ALKP 307

SPECIES

Canine

BREED

Chihuahua

COMPUTED TOMOGRAPHY OF THE SKULL

A high resolution plain CT study of the skull is provided for review.

COMPUTED TOMOGRAPHIC FINDINGS

The pictured parts of the dentition are complete and unremarkable in all jaw quadrants.

SEX

FS

A diffuse swelling of the retrobulbar tissue in the left orbit and significant soft tissue swelling of the left buccal region is appreciated, involving the caudal aspect of the left upper lip. The left ocular bulb is deviated rostrally and dorsally by the mass effect. No abnormalities of the associated osseous structures are visible.

AGE

5 Years

The nasal cavity presents the expected aerated spaces between thin & even conchae and turbinates with smooth mucosal lining.

INTERPRETED BY

Sebastian Schaub, DVM
Dr. med. vet. DipECVDI

Both temporomandibular joints present congruent joint spaces with even subchondral bone surfaces and are considered within normal limits.

Both tympanic bullae are aerated, the mucosal lining is not seen, the bony wall is smooth and thin. The external ear canals are within normal limits.

HOSPITAL NAME

Mountain West
Veterinary Hospital

The left mandibular and medial retropharyngeal lymph nodes are prominent.

COMPUTED TOMOGRAPHIC DIAGNOSIS

- Diffuse soft tissue swelling left orbit and buccal region
- Secondary left sided exophthalmos
- Lymphadenopathy left mandibular lymph nodes and left medial retropharyngeal lymph node

REFERRING VET

Staci Gustafson

INTERPRETATION OF THE FINDINGS & FURTHER RECOMMENDATIONS

Given the acute onset of clinical signs, an allergic reaction or preceding insect bite is considered likely. However, emerging abscess formation or far less likely neoplastic disease (would expect slow progressive clinical course) are differentials as well – unfortunately, further specification is not possible in plain CT.

INVOICE

52656

No foreign material is appreciated by CT.

DATE

6-30-22

Findings need to be correlated with clinical appearance and potential laboratory changes.



PATIENT

Zoey Huntsman

SPECIES

Canine

BREED

Chihuahua

SEX

FS

AGE

5 Years

INTERPRETED BY

Sebastian Schaub, DVM
Dr. med. vet. DipECVDI

HOSPITAL NAME

Mountain West
Veterinary Hospital

REFERRING VET

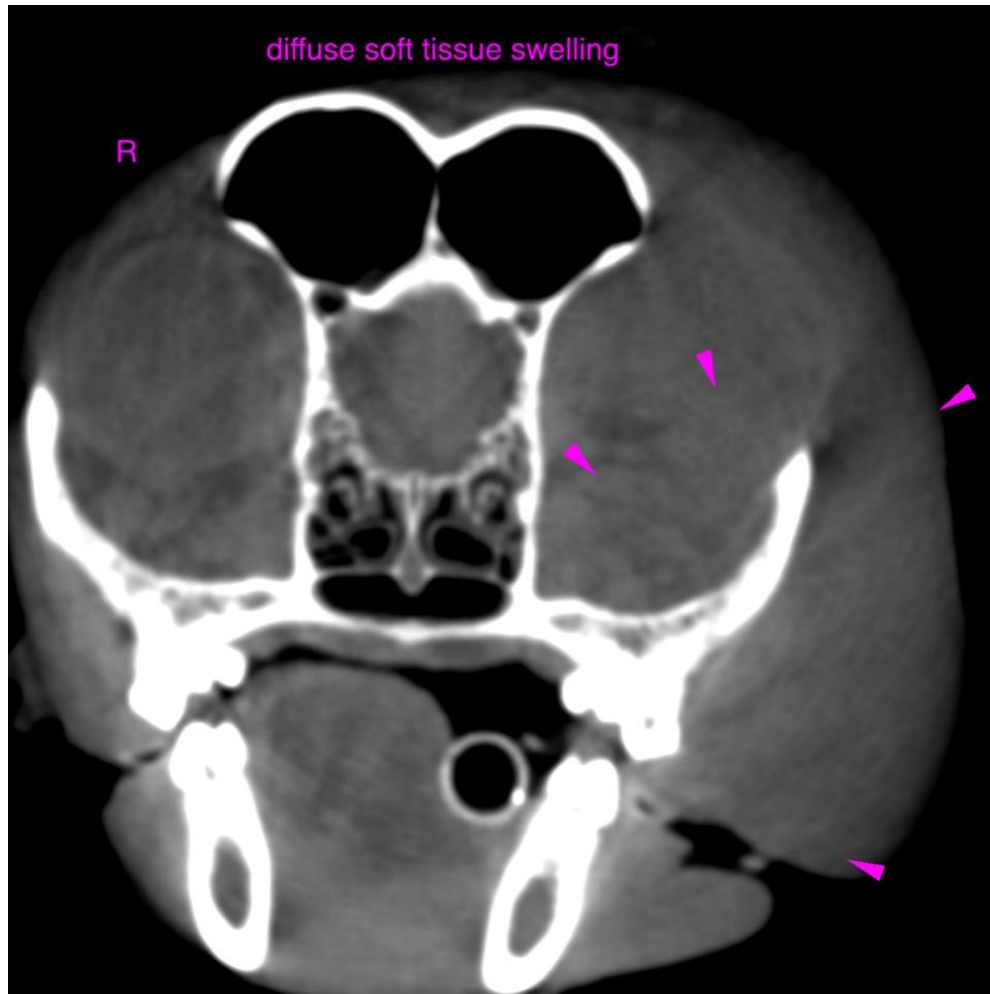
Staci Gustafson

INVOICE

52656

DATE

6-30-22



The information and recommendations provided are based on the images presented by the referring veterinarian/sonographer. No evaluation can be communicated regarding pathology that was not visible in the image/video clips provided.

Thank you for this referral. If the clinical or image interpretation does not parallel your findings or if I can be of any further assistance please contact me.

Sebastian Schaub, Sebastian Schaub, DVM, Dr. med. vet. DipECVDI
sebast.schaub@gmail.com