



PATIENT

Precious Adore a
Bully

PRESENTING CLINICAL SIGNS

mass in the mouth

SPECIES

Canine

BREED

Pitbull

SEX

Female

AGE

6 Years

INTERPRETED BY

Sebastian Schaub, DVM
Dr. med. vet. DipECVDI

COMPUTED TOMOGRAPHY OF THE SKULL

A high resolution plain CT study of the skull is provided for review.

COMPUTED TOMOGRAPHIC FINDINGS

Triadan 308&408 are absent. Arising from the gingival lining at the buccal aspect of triadan 406 to 408, a central mineralizing mass is appreciated, measuring 1.6 x 1.7 x 3.3 cm in size. Level with the mass, mild to moderate horizontal bone loss of the alveolar bone of triadan 407 is seen.

The nasal cavity presents the expected aerated spaces between thin & even conchae and turbinates with smooth mucosal lining.

Both temporomandibular joints present congruent joint spaces with even subchondral bone surfaces and are considered within normal limits.

Both tympanic bullae are aerated, the mucosal lining is not seen, the bony wall is smooth and thin. The external ear canals are within normal limits.

The brain parenchyma is homogeneous. The ventricular system is non-dilated and symmetric.

The submandibular and medial retropharyngeal lymph nodes are small and elongated with a normal short-to-long-axis-ratio is < 0.5, the attenuation pattern is uniform.

COMPUTED TOMOGRAPHIC DIAGNOSIS

- Central mineralizing gingival mass, buccal aspect right mandible
- Absent triadan 308 & 408

HOSPITAL NAME

Animal Surgical
Center

INTERPRETATION OF THE FINDINGS & FURTHER RECOMMENDATIONS

The mineralizing (pedunculated) mass at the buccal aspect of the right mandible can present ossifying epulis/fibromatous epulis of periodontal ligament origin. As there are no signs for overt aggressive biological behavior, the odds for malignant neoplastic disease are considered low. Recommend excisional biopsy for further workup and ruling out malignant disease entirely.

REFERRING VET

Dr. Kam

INVOICE

52664

DATE

6-30-22



PATIENT

Precious Adore a
Bully

SPECIES

Canine

BREED

Pitbull

SEX

Female

AGE

6 Years

INTERPRETED BY

Sebastian Schaub, DVM
Dr. med. vet. DipECVDI

HOSPITAL NAME

Animal Surgical
Center

REFERRING VET

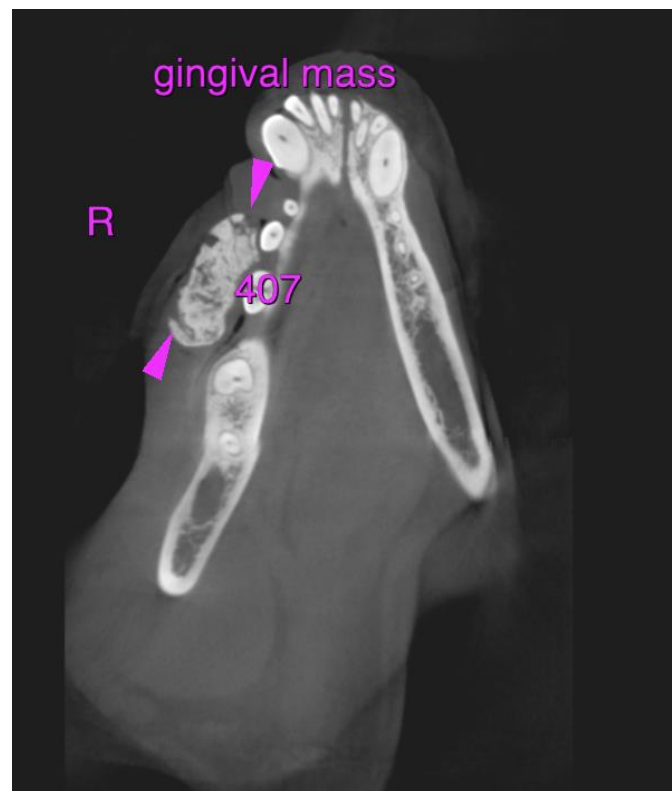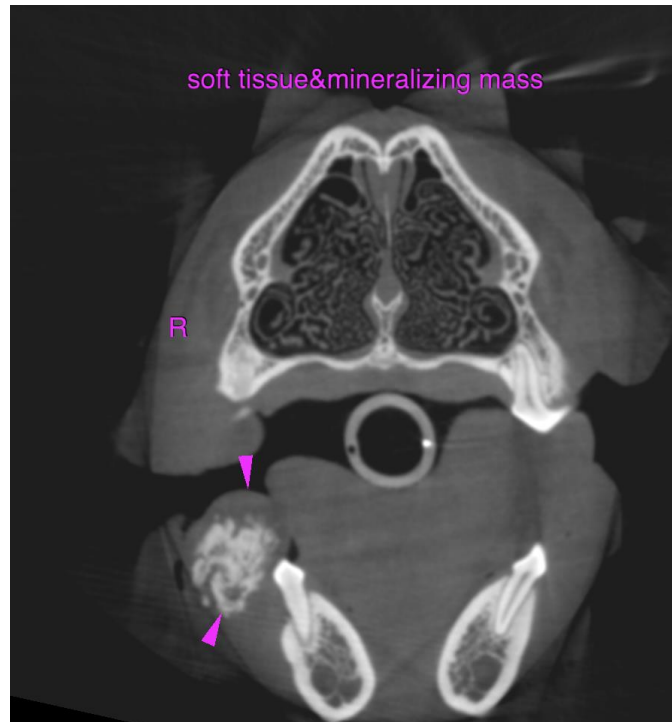
Dr. Kam

INVOICE

52664

DATE

6-30-22





PATIENT

Precious Adore a
Bully

SPECIES

Canine

BREED

Pitbull

SEX

Female

AGE

6 Years

INTERPRETED BY

Sebastian Schaub, DVM
Dr. med. vet. DipECVDI

HOSPITAL NAME

Animal Surgical
Center

REFERRING VET

Dr. Kam

INVOICE

52664

DATE

6-30-22

The information and recommendations provided are based on the images presented by the referring veterinarian/sonographer. No evaluation can be communicated regarding pathology that was not visible in the image/video clips provided.

Thank you for this referral. If the clinical or image interpretation does not parallel your findings or if I can be of any further assistance please contact me.

Sebastian Schaub, Sebastian Schaub, DVM, Dr. med. vet. DipECVDI
sebast.schaub@gmail.com