



## PATIENT

Zazzy Elkins

## SPECIES

Feline

## BREED

Ragdoll

## SEX

FS

## AGE

14Y

## WEIGHT

8lbs

## INTERPRETED BY

Sebastian Schaub, DVM  
Dr. med. vet.  
DipECVDI

## IMAGING PERFORMED BY

Vet Techs

## HOSPITAL NAME

Northshore Veterinary  
Hospital

## REFERRING VET

Brita Kiffney

## INVOICE

75284

## DATE

6-3-26

## PRESENTING CLINICAL SIGNS

decreased appetite and weight loss over three months

Abnormal PE/Chem/CBC/UA Results: cbc normal chem normal TT4 2 Abdominal ultrasound reveals moderately thickened small intestines and mesenteric lymphadenopathy

## RADIOGRAPHIC STUDY OF THE THORAX & ABDOMEN

An overview study of the thorax and abdomen in orthogonal image planes is provided for review.

## RADIOGRAPHIC FINDINGS

### Thorax

Along the thoracic spine, multifocal mild spondylosis formation is seen.

The extrathoracic soft tissues present homogeneous without abnormalities.

The heart is of normal size and shape; there is no evidence of cardiac chamber or vascular enlargement. The pulmonary vasculature is within normal limits.

The trachea is normal in diameter and presents the anticipated course. The luminal outline of the trachea is smooth.

The bronchial tree presents with thin walls and tapers uniformly towards the periphery as expected.

The lung parenchyma presents the expected architecture and opacity; the intrapulmonary vascular branching is seen up to the third order lung vessels.

The diaphragm is well delineated with even surface and the expected mild cranial bulging of the diaphragmatic cupola.

### Abdomen

The vertebral endplates of the lumbosacral junction present mild spondylosis formation.

No abnormalities of the extraabdominal soft tissues are noted. The abdominal wall is smooth and thin – a wet fur artefact is appreciated along the caudoventral abdominal wall.

The serosal detail is maintained throughout the peritoneal and retroperitoneal space.

The liver is appropriate in position, size and presents uniform opacity.

The splenic head is in the anticipated position and within normal limits for size and opacity. The splenic body and tail are considered normal for position, size, shape and opacity.

Both kidneys are seen and present mild irregular margins, R>L. The volume of both kidneys is mildly decreased. In the image plane of the renal pelvis of both kidneys, a small amount of mineral opaque material is noted. The urinary bladder is in its anticipated position. No radiopaque calculi are noted throughout the upper and lower urinary tract.

The stomach is in its anticipated position and presents normal content.

The small intestinal loops are of even diameter and non-dilated, a small amount of gas is seen within the small intestinal loops and considered within normal limits.

The colon is seen in the expected position and presents with appropriate content.



## PATIENT

Zazzy Elkins

## SPECIES

Feline

## BREED

Ragdoll

## SEX

FS

## AGE

14Y

## WEIGHT

8lbs

## INTERPRETED BY

Sebastian Schaub, DVM  
Dr. med. vet.  
DipECVDI

## IMAGING PERFORMED BY

Vet Techs

## HOSPITAL NAME

Northshore Veterinary  
Hospital

## REFERRING VET

Brita Kiffney

## INVOICE

75284

## DATE

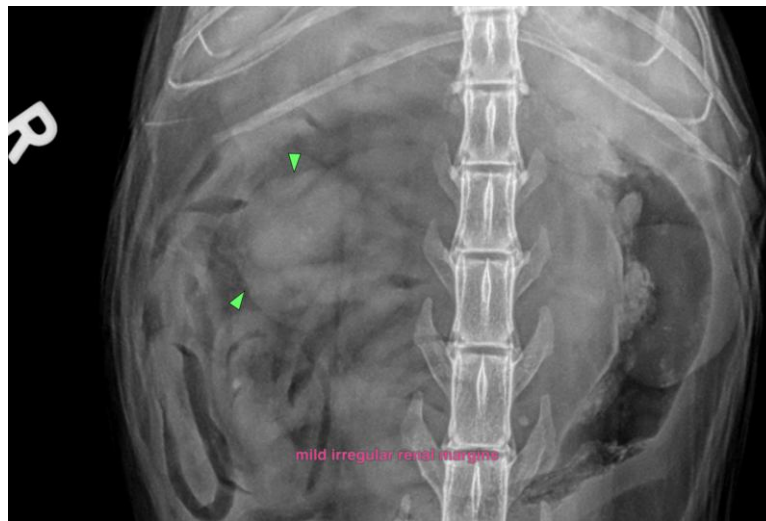
6-3-26

## RADIOGRAPHIC DIAGNOSIS

- Chronic nephropathy
- Mild nephrolithiasis
- Spondylosis deformans

## INTERPRETATION OF THE FINDINGS & FURTHER RECOMMENDATIONS

The radiographic study reveals no specific abnormalities with the main finding being the chronic nephropathy. An abdominal ultrasound examination has already been performed and there was no evidence of mechanical ureteral obstruction.



The information and recommendations provided are based on the images presented by the referring veterinarian/sonographer. No evaluation can be communicated regarding pathology that was not visible in the image/video clips provided.

Thank you for this referral. If the clinical or image interpretation does not parallel your findings or if I can be of any further assistance please contact me.

**Sebastian Schaub**, Sebastian Schaub, DVM, Dr. med. vet. DipECVDI  
[info@sonopath.com](mailto:info@sonopath.com)