



PATIENT PRESENTING CLINICAL SIGNS

Revy Wilcutts History: Grade 3-4 lame L hind and O reports that P will occasionally prop leg out while sitting. Duration of 3-4 days with progressive lameness. Quite active in general, goes hiking, but no recently observed trauma. Sensitivity to palpation of femur.

SPECIES Abnormal PE/Chem/CBC/UA Results:

Canine **RADIOGRAPHIC STUDY OF THE PELVIS AND STIFLE JOINTS**

A complete set of radiographs of the pelvis and stifle joints is provided for review.

BREED RADIOGRAPHIC FINDINGS

GSD Both coxofemoral joints present a mild widening of the joint space with resultant mild incongruity. The osseous margins of both coxofemoral joints are smooth.

SEX The medullary cavity of the femoral diaphysis bilaterally presents a patchy/cloudy myelosclerosis. At Male the caudal cortex of the distal diaphysis of the left femur, mild immature periosteal new bone formation is noted. Fingerprint like sclerosis of the medullary cavity of the proximal diaphysis of the left tibia level with the nutritional foramen is seen.

AGE Both stifle joints present smooth osseous margins and no evidence of intracapsular swelling. 1 Year

RADIOGRAPHIC DIAGNOSIS

INTERPRETED BY

Sebastian Schaub,
DVM Dr. med. vet.
DipECVDI

- Significant myelosclerosis of the femoral diaphysis bilaterally
- Mild active periosteal new bone formation caudal aspect diaphysis of left femur
- Patchy myelosclerosis of the left proximal tibial diaphysis
- Mild incongruity of the coxofemoral joints

HOSPITAL NAME

Boca Park AH

INTERPRETATION OF THE FINDINGS & FURTHER RECOMMENDATIONS

The radiographic changes are consistent with marked panosteitis – being a plausible explanation for the presenting clinical signs. Recommend empirical management including NSAID and if needed dietary changes. The disease is self-limiting, but flare-ups can be associated with significant pain.

REFERRING VET

Dr. Hill

INVOICE

15889

DATE

6/3/22



PATIENT

Revy Wilcutts

SPECIES

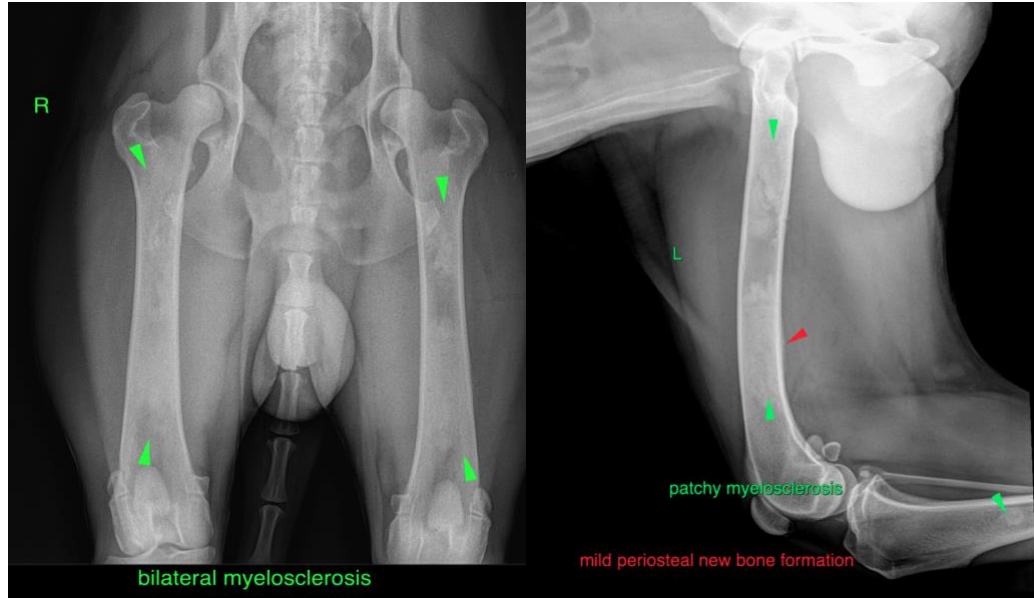
Canine

BREED

GSD

SEX

Male



AGE

1 Year

The information and recommendations provided are based on the images presented by the referring veterinarian/sonographer. No evaluation can be communicated regarding pathology that was not visible in the image/video clips provided.

Thank you for this referral. If the clinical or image interpretation does not parallel your findings or if I can be of any further assistance please contact me.

INTERPRETED BY

Sebastian Schaub,
DVM Dr. med. vet.
DipECVDI

Sebastian Schaub, Sebastian Schaub, DVM, Dr. med. vet. DipECVDI
sebast.schaub@gmail.com

HOSPITAL NAME

Boca Park AH

REFERRING VET

Dr. Hill

INVOICE

15889

DATE

6/3/22