



PATIENT PRESENTING CLINICAL SIGNS

Garth King Intermittent coughing at home, has gotten slightly worse over the past few months. Radiographs initially taken April 20th. Did steroid trial - slight improvement over the past month, but persistent coughing (episodes every 3-7 days).

SPECIES RADIOGRAPHIC STUDY OF THE THORAX

Feline Radiographs of the thorax in three imaging planes are provided for review.

RADIOGRAPHIC FINDINGS

BREED The surrounding bony structures are within normal limits.

DSH The extrathoracic soft tissues present homogeneous without abnormalities.

SEX The heart is of normal size and shape, there is no evidence of cardiac chamber or vascular enlargement. The pulmonary vasculature is within normal limits. The aortic arch presents mild lateral bending and is mildly superimposed on the left cranial lung lobe in the VD view.

MN The trachea is normal in diameter and presents the anticipated course. The luminal outline of the trachea is smooth.

AGE The bronchial tree presents with thin walls and tapers uniformly towards the periphery as expected.

5 Years The lung parenchyma presents the expected architecture and opacity; the intrapulmonary vascular branching is seen up to the third order lung vessels. In the lateral views, the volume of the lung field is mildly increased – not appreciated in the VD projection.

INTERPRETED BY

Sebastian Schaub, DVM
Dr. med. vet. DipECVDI

The diaphragm is well delineated with even surface and the expected mild cranial bulging of the diaphragmatic cupola.

HOSPITAL NAME RADIOGRAPHIC DIAGNOSIS

Gentle Doctor Animal
Hospital

- Equivocal mild hyperinflation of the lung
- Mild redundancy of the aortic arch, incidental

INTERPRETATION OF THE FINDINGS & FURTHER RECOMMENDATIONS

REFERRING VET

Dr Miranda
Thomassen

The radiographic study of the thorax presents no specific abnormalities, but subjective mild increased volume of the lung in the lateral views – radiographs might be taken during maximum inspiration as potential. Although the lung parenchyma presents without additional changes, negative thoracic radiographs do not rule out inflammatory lower airway disease entirely.

INVOICE

52304

DATE

6-3-22



PATIENT

Garth King

SPECIES

Feline

BREED

DSH

SEX

MN

AGE

5 Years

INTERPRETED BY

Sebastian Schaub, DVM
Dr. med. vet. DipECVDI

HOSPITAL NAME

Gentle Doctor Animal
Hospital

REFERRING VET

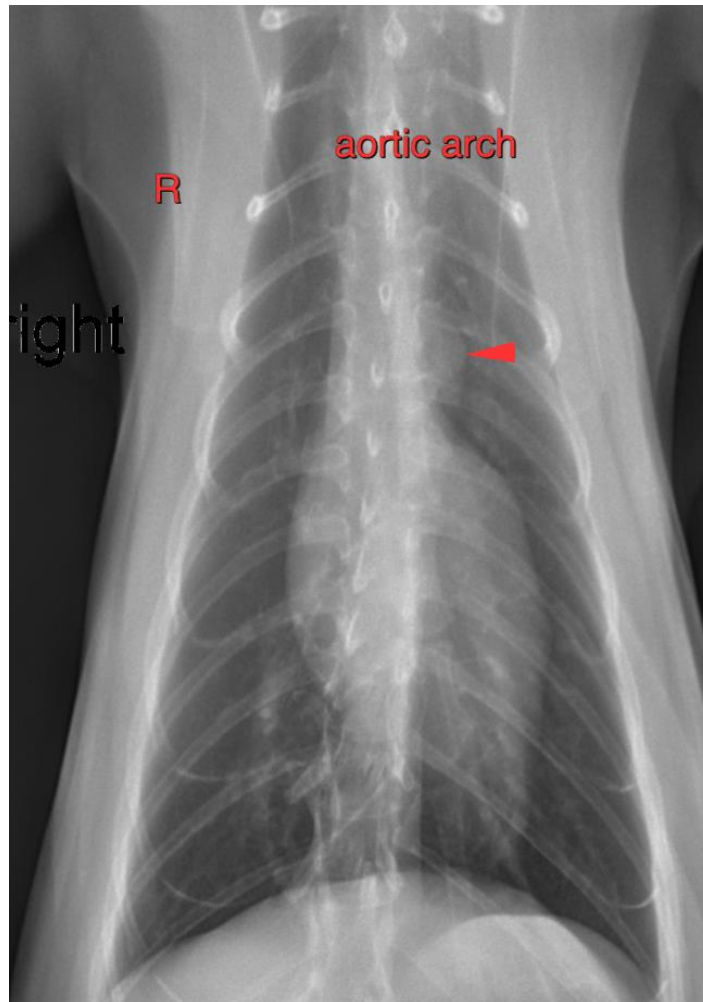
Dr Miranda
Thomassen

INVOICE

52304

DATE

6-3-22



The information and recommendations provided are based on the images presented by the referring veterinarian/sonographer. No evaluation can be communicated regarding pathology that was not visible in the image/video clips provided.

Thank you for this referral. If the clinical or image interpretation does not parallel your findings or if I can be of any further assistance please contact me.

Sebastian Schaub, Sebastian Schaub, DVM, Dr. med. vet. DipECVDI
sebast.schaub@gmail.com