



PATIENT PRESENTING CLINICAL SIGNS

Enzo Liquori History: Presented for decrease appetite and hiccups/intermittent panting. Starting 48 hours ago, P started having diarrhea and stopped eating. O has offered all of his favorite treats and his not interested. O also reports P is constantly panting and seems to get "hiccups" when he is laying down. O report PU/PD with very dilute urine. P is on Pepcid AC for sensitive stomach, Galliprant, Adequan, Gabapentin. History of OA and receives acupuncture and laser therapy.

SPECIES

Canine

BREED

Husky

Abnormal PE/Chem/CBC/UA Results: Today: CBC - LYM 0.93 (1-4.8) L, NEU 14.1 (3-12) H Chem - AMY 131 (200-1200) L, PHOS 2.6 (2.9-6.6) L UA - pending (UA appears concentrated on cysto) P intermittently tense and slightly reactive/vocal to caudal abdominal palpation. Repeatable. Skin - patchy erythemic lesion on inguinal area with mild generalized erythema. Ecchymosis? erythemic are flush with skin, not raised, contained to inguinal region. Rectal -- loose stool/diarrhea.

RADIOGRAPHIC STUDY OF THE ABDOMEN

SEX

Neutered Male

Radiographs of the abdomen in three imaging planes are provided for review.

RADIOGRAPHIC FINDINGS

AGE

9.75 Years

Moderate spondylosis formation is seen along the thoracolumbar junction. The intervertebral disc spaces T11/T12 to Th13/L1 and L3/L4 are moderately narrowed. A metal opaque cramp is seen superimposed on the stifle joints bilaterally.

INTERPRETED BY

Sebastian Schaub,
DVM Dr. med. vet.
DipECVDI

No abnormalities of the extraabdominal soft tissues are noted. The abdominal wall is smooth and thin. The serosal detail is maintained throughout the peritoneal and retroperitoneal space.

The liver is appropriate in position, size and presents uniform opacity.

HOSPITAL NAME

Boca Park AH

The splenic head is in the anticipated position and within normal limits for size and opacity. The splenic body and tail are considered normal for position, size, shape and opacity.

Both kidneys are seen and present with normal size, shape, delineation and opacity. The urinary bladder is in its anticipated position. No radiopaque calculi are noted throughout the upper and lower urinary tract.

REFERRING VET

Dr. Ashman

The stomach is in its anticipated position and presents normal content.

INVOICE

15892

The small intestinal loops are of even diameter and non-dilated, a small amount of gas is seen within the small intestinal loops and considered within normal limits.

The colon is seen in the expected position and presents with appropriate content.

DATE

6/3/22

RADIOGRAPHIC DIAGNOSIS



PATIENT

Enzo Liquori

- Discopathy T11/T12 to T13/L1 and L3/L4
- History of surgical stabilization of cranial cruciate ligament failure by an extracapsular suture technique
- Spondylosis deformans

SPECIES

Canine

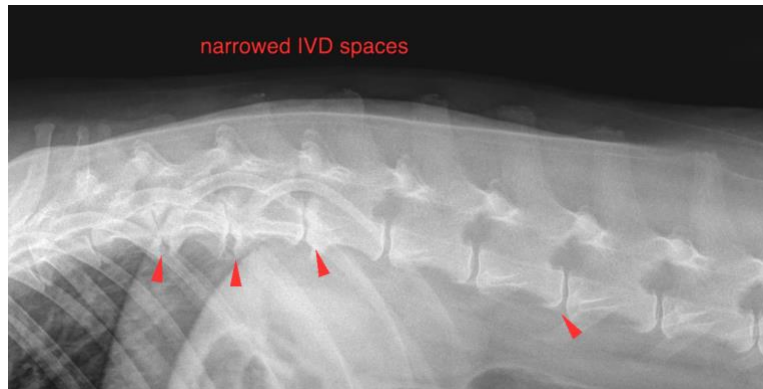
Husky

Neutered Male

9.75 Years

INTERPRETATION OF THE FINDINGS & FURTHER RECOMMENDATIONS

The radiographic study of the abdomen presents no specific abnormalities, explaining the presenting clinical signs and the presumptive diagnosis is gastroenteritis. If not done so yet, complementing lab work by cpl can be used to rule out underlying pancreatitis. Check if pain can be elicited on clinical examination of the spine.



The information and recommendations provided are based on the images presented by the referring veterinarian/sonographer. No evaluation can be communicated regarding pathology that was not visible in the image/video clips provided.

INTERPRETED BY

Sebastian Schaub,
DVM Dr. med. vet.
DipECVDI

HOSPITAL NAME

Boca Park AH

Thank you for this referral. If the clinical or image interpretation does not parallel your findings or if I can be of any further assistance please contact me.

REFERRING VET

Dr. Ashman

Sebastian Schaub, Sebastian Schaub, DVM, Dr. med. vet. DipECVDI
sebast.schaub@gmail.com

INVOICE

15892

DATE

6/3/22