



PATIENT PRESENTING CLINICAL SIGNS

Boogie Licari
 Stray cat Hx of Chronic URI. unresponsive to the ABS,
 Abnormal PE/Chem/CBC/UA Results: Heavy bilateral nasal dc

SPECIES COMPUTED TOMOGRAPHY OF THE SKULL

Feline
 A high resolution pre- and post-contrast CT study of the skull is provided for review.

COMPUTED TOMOGRAPHIC FINDINGS

BREED
 A supernumerary triadan 205 is noted.

DSH
 In both nasal cavities, a moderate amount of fluid attenuating material is attached to the nasal mucosal lining. Advanced destruction of the nasal conchal & turbinate structures is present. Post contrast administration, the nasal mucosal lining is moderately thickened.

SEX
 Both temporomandibular joints present congruent joint spaces with even subchondral bone surfaces and are considered within normal limits.

MC
 The left tympanic bulla is filled with fluid attenuating material, the osseous lining of the left tympanic bulla is smooth and thin. In both external ear canals, a mild amount of non-contrast enhancing soft tissue material is attached to the epithelial lining.

AGE
 4 Years
 The brain presents no deviation from normal anatomy and symmetry. The brain parenchyma is homogeneous and within normal limits for attenuation and distribution of contrast enhancement. The ventricular system is non-dilated and symmetric.

INTERPRETED BY

Sebastian Schaub, DVM
 Dr. med. vet. DipECVDI

The submandibular and medial retropharyngeal lymph nodes are prominent.

COMPUTED TOMOGRAPHIC DIAGNOSIS

HOSPITAL NAME

Animal Clinic of
 Queens

- Destructive rhinitis
- Lymphadenopathy mandibular and medial retropharyngeal lymph nodes bilaterally
- Left sided otitis media
- Bilateral mild otitis externa
- Supernumerary triadan 205

REFERRING VET

Dr Piotr Kwasnik

INTERPRETATION OF THE FINDINGS & FURTHER RECOMMENDATIONS

The findings are consistent with chronic destructive rhinitis. The causative agent is most likely primary viral ± bacterial superinfection. Even though less likely, here is a small chance of emerging fungal (cryptococcal) superinfection.

INVOICE

52303

Secondary left sided otitis media, due to ascending infection by the Eustachian tube. There is no evidence of polyp formation.

The prominent mandibular & medial retropharyngeal lymph nodes are consistent with secondary reactive lymphadenitis due to the underlying chronic rhinitis.

DATE

6-3-22

Rhinoscopy with biopsy and samples for microbial cultures is recommended would be ideal for further workup. In cases of chronic rhinosinusitis, clinical signs are likely to reoccur.



PATIENT

Boogie Licari

SPECIES

Feline

BREED

DSH

SEX

MC

AGE

4 Years

INTERPRETED BY

Sebastian Schaub, DVM
Dr. med. vet. DipECVDI

HOSPITAL NAME

Animal Clinic of
Queens

REFERRING VET

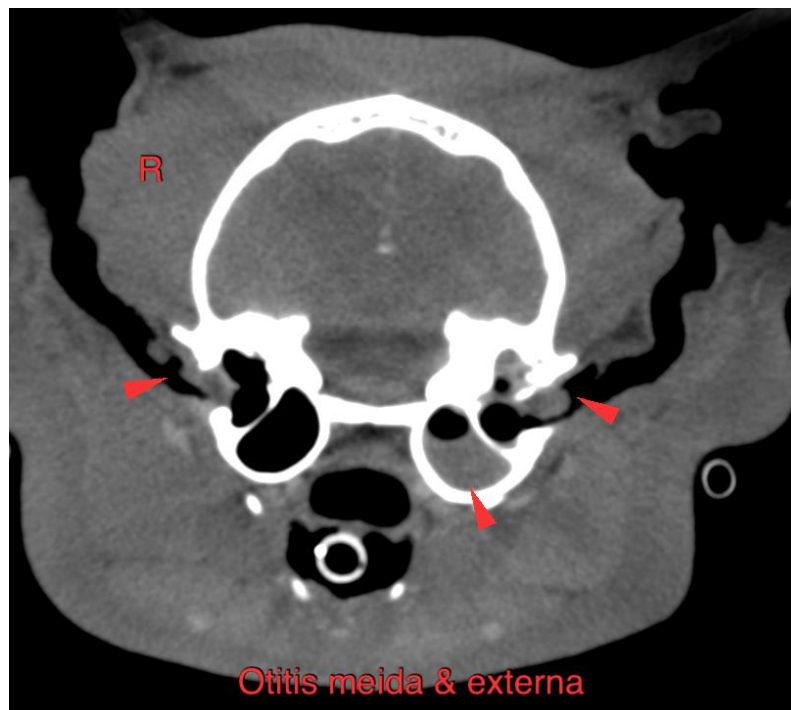
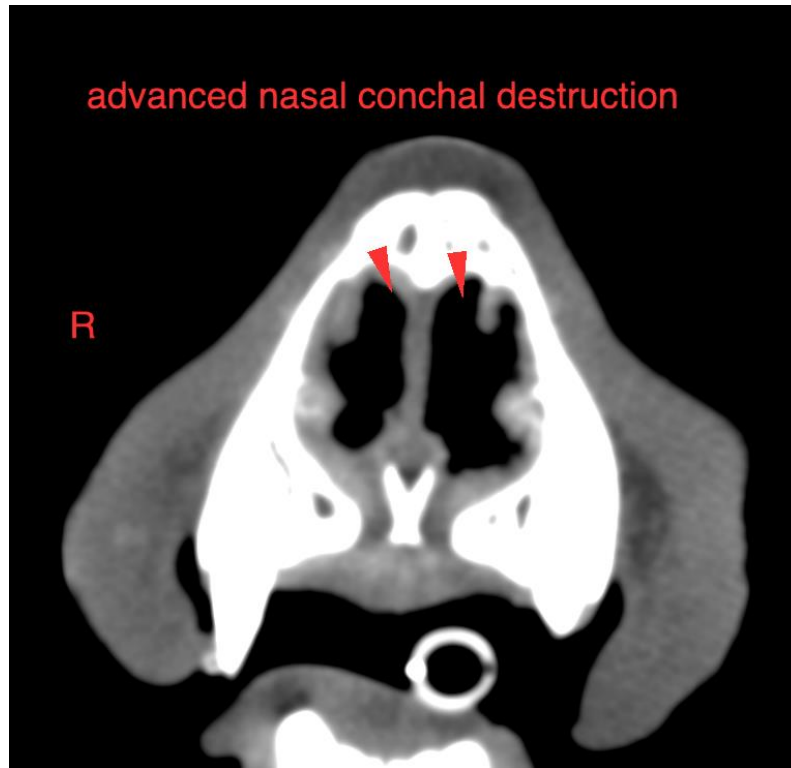
Dr Piotr Kwasnik

INVOICE

52303

DATE

6-3-22





PATIENT

Boogie Licari

SPECIES

Feline

The information and recommendations provided are based on the images presented by the referring veterinarian/sonographer. No evaluation can be communicated regarding pathology that was not visible in the image/video clips provided.

BREED

DSH

Thank you for this referral. If the clinical or image interpretation does not parallel your findings or if I can be of any further assistance please contact me.

Sebastian Schaub, Sebastian Schaub, DVM, Dr. med. vet. DipECVDI
sebast.schaub@gmail.com

SEX

MC

AGE

4 Years

INTERPRETED BY

Sebastian Schaub, DVM
Dr. med. vet. DipECVDI

HOSPITAL NAME

Animal Clinic of
Queens

REFERRING VET

Dr Piotr Kwasnik

INVOICE

52303

DATE

6-3-22