



PATIENT PRESENTING CLINICAL SIGNS

Luna Maupin
SPECIES History: Luna has been limping on her right hind leg for a couple months. Shasta said that she has her sister as well and she is doing the same on her left hind. Luna will run and play on it just fine but when she is walking around it kind of drags or looks like her hip is coming out of socket. She hasn't had this issue in the past. Everything else is normal with Luna. Shasta just wants to make sure she isn't in pain but thinks she has the genetic disorder hip dysplasia.

Canine

BREED

Abnormal PE/Chem/CBC/UA Results:- Walking in crouched position in hindlimbs with exaggerated abduction of R hindlimb - No pain elicited with palpation of spine or manipulation of hindlimbs
 Labs pending

German Shepherd

RADIOGRAPHIC STUDY OF THE LUMBAR SPINE, PELVIS AND STIFLE JOINTS

SEX

A complete set of radiographs of the lumbar spine, pelvis and the stifle joints is provided for review.

Female

RADIOGRAPHIC FINDINGS

The last lumbar vertebra is counted as L7.

AGE

4 Years 2 Months

The vertebral endplates L5/L6 present moderate spondylosis formation and the respective intervertebral disc space is narrowed. The remainder of the osseous and soft tissue structures of the lumbar spine are within normal limits.

INTERPRETED BY

Sebastian Schaub,
 DVM Dr. med. vet.
 DipECVDI

The osseous and surrounding soft tissue structures of the pelvis are within normal limits. Both coxofemoral joints present mild osteophyte new bone formation. The coxofemoral joint space bilaterally is mildly incongruent and diverging medially.

The stifle joints bilaterally have smooth osseous margins and present no signs for intracapsular soft tissue swelling.

HOSPITAL NAME

Elizabeth AH

RADIOGRAPHIC DIAGNOSIS

- Chronic discopathy L5/L6
- Mild degenerative osteoarthritis coxofemoral joints bilaterally, due to mild hip dysplasia

REFERRING VET

Jennifer Redus, DVM

INTERPRETATION OF THE FINDINGS & FURTHER RECOMMENDATIONS

The narrowed intervertebral disc space and degenerative osseous remodeling L5/L6 indicates chronic discopathy, that might or might not be associated with compressive myelopathy.

INVOICE

23137

The clinical relevance of the mild degenerative joint disease of the coxofemoral joints due to mild hip dysplasia is unclear – correlate with findings of the clinical examination.

DATE

6/29/23



PATIENT

Luna Maupin

SPECIES

Canine

BREED

German Shepherd

SEX

Female

AGE

4 Years 2 Months

INTERPRETED BY

Sebastian Schaub,
DVM Dr. med. vet.
DipECVDI

HOSPITAL NAME

Elizabeth AH

REFERRING VET

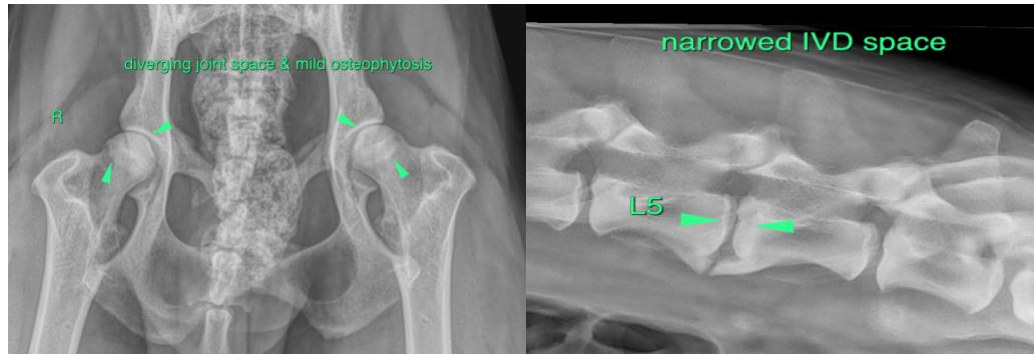
Jennifer Redus, DVM

INVOICE

23137

DATE

6/29/23



The information and recommendations provided are based on the images presented by the referring veterinarian/sonographer. No evaluation can be communicated regarding pathology that was not visible in the image/video clips provided.

Thank you for this referral. If the clinical or image interpretation does not parallel your findings or if I can be of any further assistance please contact me.

Sebastian Schaub, Sebastian Schaub, DVM, Dr. med. vet. DipECVDI
info@sonopath.com