



**PATIENT**

Nutters Nielsen

**PRESENTING CLINICAL SIGNS**

O stated that Pt came home yesterday limping on LH (Pt is indoor/outdoor). O stated that Pt is usually very active - but now has not been wanting to jump up onto anything - hiding which is unusual. O stated that Pt has not been eating as much.

**SPECIES**

Feline

**RADIOGRAPHIC STUDY OF THE LEFT STIFE JOINT**

Radiographs of the left stifle joint in two imaging planes are provided for review.

**BREED**

DSH

The growth plates are age related visible.

**SEX**

MN

Superimposed on the cranial compartment of the left stifle joint, a well-defined ovoid shaped mineralized body measuring 1.8 mm in size is appreciated. The left stifle joint presents evidence of mild intracapsular soft tissue swelling, distorting the infrapatellar fat-pad. The soft tissues at the medial aspect of the left stifle joint present an increased volume in comparison to the contralateral limb.

**AGE**

1 Year

**RADIOGRAPHIC DIAGNOSIS**

- Mild articular swelling left stifle joint
- Soft tissue swelling medial aspect of the left stifle joint
- Suspect meniscal mineralization left stifle joint

**INTERPRETED BY**

Sebastian Schaub, DVM  
Dr. med. vet. DipECVDI

**INTERPRETATION OF THE FINDINGS & FURTHER RECOMMENDATIONS**

There is evidence of mild joint effusion of the left stifle joint which can be traumatic, degenerative, or inflammatory in origin. Due to acute onset of clinical signs and the soft tissue swelling medially, rule out soft tissue trauma (e.g. bite wound, hematoma) or primary disease of the left stifle joint, such as distortion or pathology of the cranial cruciate ligament.

**HOSPITAL NAME**

POCONO PEAK  
VETERINARY  
CENTER

The meniscal mineralization is commonly an incidental finding.

**REFERRING VET**

Dr. Christine Coyle

**INVOICE**

52619

**DATE**

6-28-22



**PATIENT**

Nutters Nielsen

**SPECIES**

Feline

**BREED**

DSH

**SEX**

MN

**AGE**

1 Year

**INTERPRETED BY**

Sebastian Schaub, DVM  
Dr. med. vet. DipECVDI

**HOSPITAL NAME**

POCONO PEAK  
VETERINARY  
CENTER

**REFERRING VET**

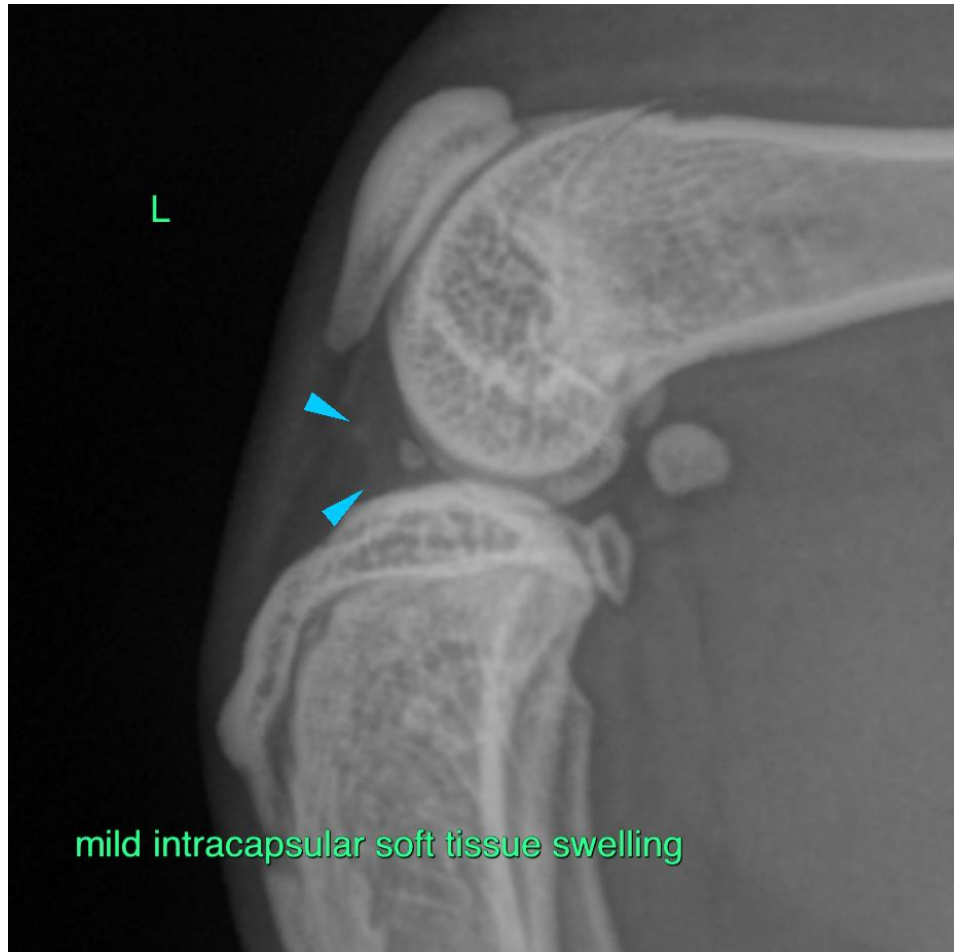Dr. Christine Coyle

**INVOICE**

52619

**DATE**

6-28-22





**PATIENT**

Nutters Nielsen

**SPECIES**

Feline

**BREED**

DSH

**SEX**

MN

**AGE**

1 Year

**INTERPRETED BY**

Sebastian Schaub, DVM  
Dr. med. vet. DipECVDI

**HOSPITAL NAME**

POCONO PEAK  
VETERINARY  
CENTER

**REFERRING VET**

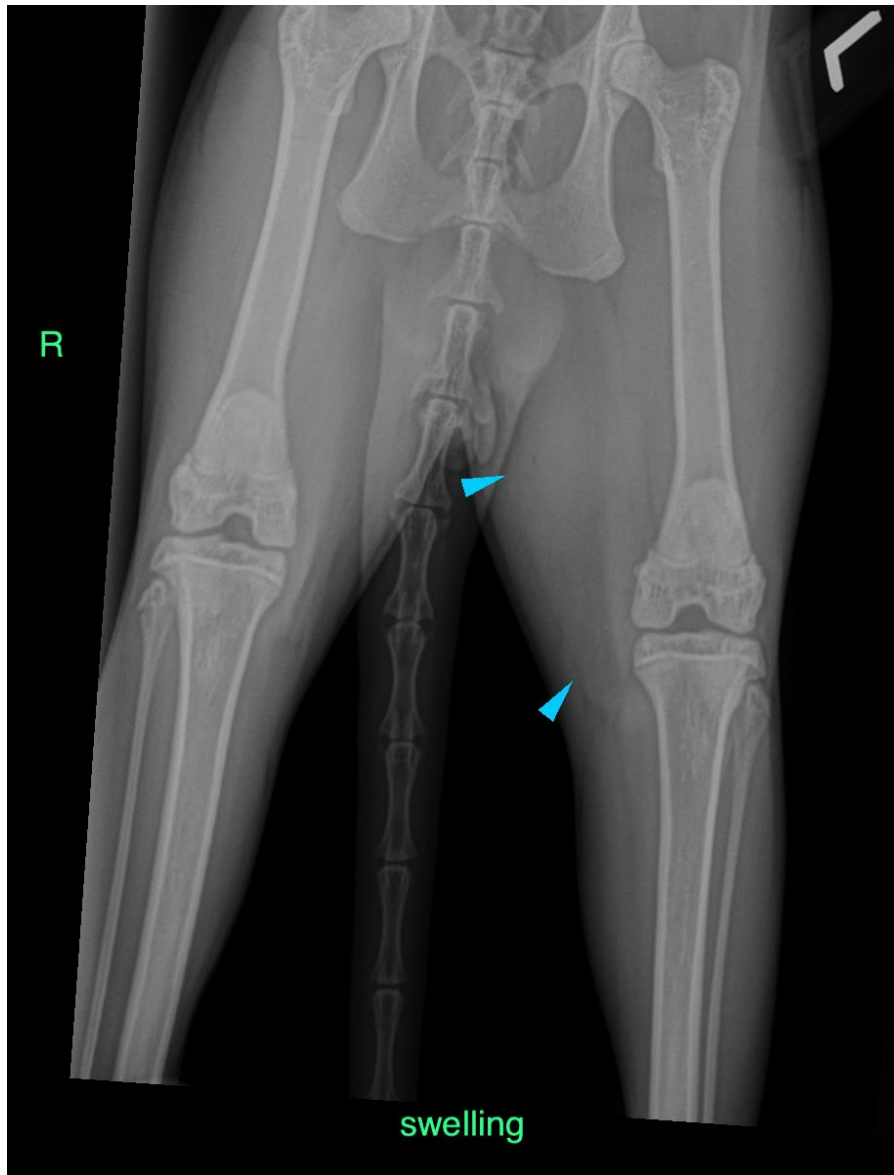
Dr. Christine Coyle

**INVOICE**

52619

**DATE**

6-28-22



The information and recommendations provided are based on the images presented by the referring veterinarian/sonographer. No evaluation can be communicated regarding pathology that was not visible in the image/video clips provided.

Thank you for this referral. If the clinical or image interpretation does not parallel your findings or if I can be of any further assistance please contact me.

**Sebastian Schaub**, Sebastian Schaub, DVM, Dr. med. vet. DipECVDI  
sebast.schaub@gmail.com