

**PATIENT**

Cersei McKeen

PRESENTING CLINICAL SIGNS

3 week history of swelling over tarsus; no lameness; joint tap normal. Suspicious of OCD lesion
Abnormal PE/Chem/CBC/UA Results: na

SPECIES

Canine

RADIOGRAPHIC STUDY OF THE TARSAL JOINTS

Radiographs of both tarsal joints in two imaging planes are provided for review.

BREED

Boerboel

The growth plates are age related open.

SEX

Female

The left tibiotarsal joint presents with a significant intracapsular soft tissue swelling. Along the medial malleolus of the left tarsal joint, mild to moderate osteophyte new bone formation is appreciated. The medial compartment of the left tibiotarsal joint is widened and the medial trochlear ridge of the talus appears shallow.

The osseous and surrounding soft tissue structures of the right tarsal joint are within normal limits.

RADIOGRAPHIC DIAGNOSIS

- Suspect osteochondrosis dissecans (OCD) medial trochlear ridge left talus
- Secondary mild degenerative osteoarthritis left talocrural joint
- Significant articular swelling left talocrural joint

AGE

8 Months

INTERPRETED BY

Sebastian Schaub, DVM
Dr. med. vet. DipECVDI

INTERPRETATION OF THE FINDINGS & FURTHER RECOMMENDATIONS

The radiographic changes are supporting the diagnosis of OCD lesion of the medial trochlear ridge of the left talus with secondary joint effusion and mild to moderate degenerative osteoarthritis. Unfortunately, the calcaneus is superimposed on the medial compartment of the left tibiotarsal joint, limiting contrast of the osseous structures. Repeating the dorsoplantar view of the left tarsal joint with mild supination of the calcaneus will improve visibility of the medial compartment of the left tarsal joint.

A CT study of the tarsal joint can be used as advanced imaging modality as well.

HOSPITAL NAME

Lac Ste. Anne
Veterinary Services

REFERRING VET

Dr. K. McIntosh

INVOICE

52637

DATE

6-28-22



PATIENT

Cercei McKeen

SPECIES

Canine

BREED

Boerboel

SEX

Female

AGE

8 Months

INTERPRETED BY

Sebastian Schaub, DVM
Dr. med. vet. DipECVDI

HOSPITAL NAME

Lac Ste. Anne
Veterinary Services

REFERRING VET

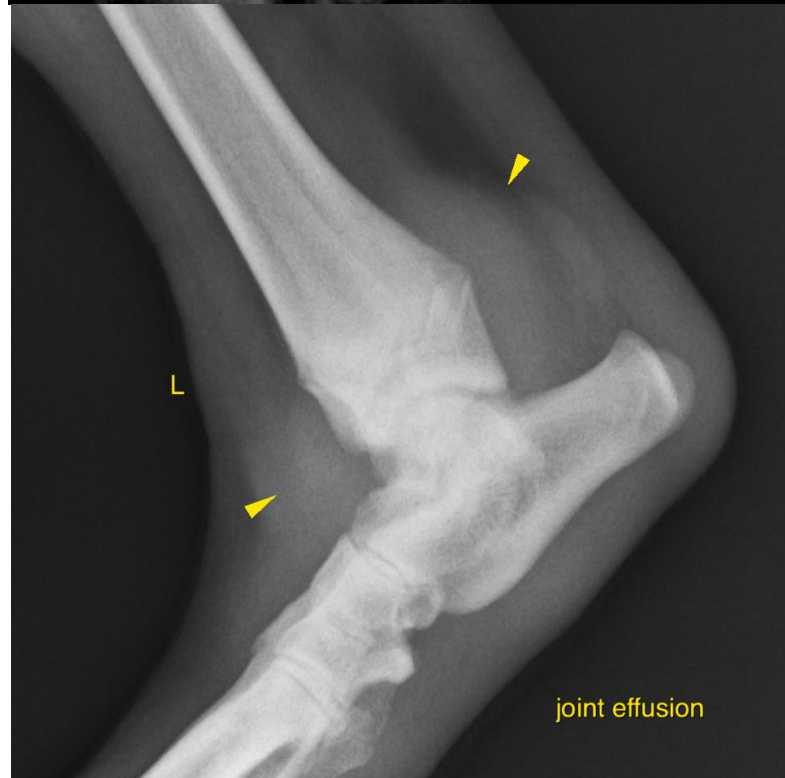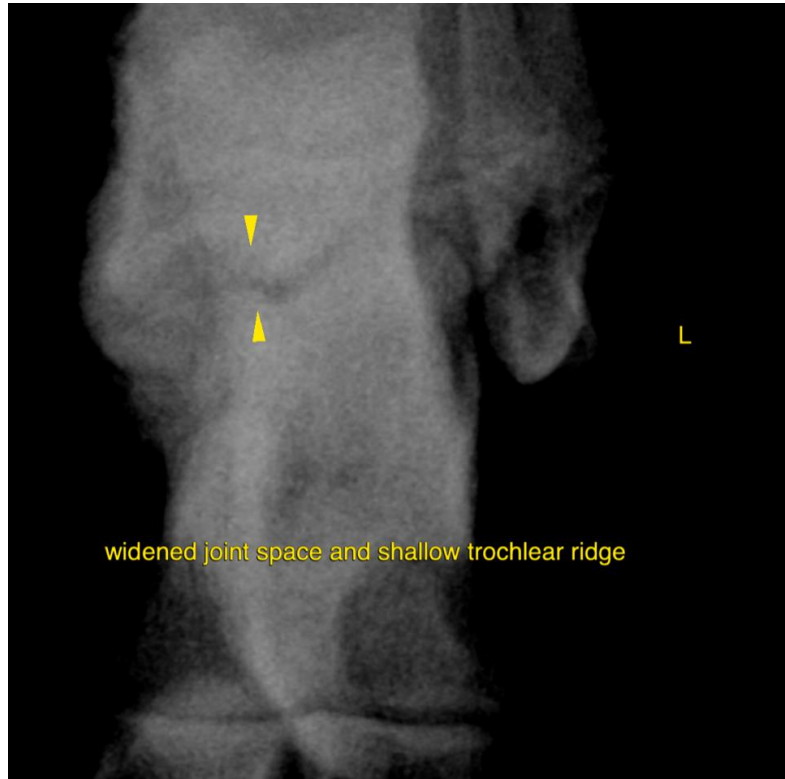
Dr. K. McIntosh

INVOICE

52637

DATE

6-28-22





PATIENT

Cercei McKeen

The information and recommendations provided are based on the images presented by the referring veterinarian/sonographer. No evaluation can be communicated regarding pathology that was not visible in the image/video clips provided.

SPECIES

Canine

Thank you for this referral. If the clinical or image interpretation does not parallel your findings or if I can be of any further assistance please contact me.

Sebastian Schaub, Sebastian Schaub, DVM, Dr. med. vet. DipECVDI
sebast.schaub@gmail.com

BREED

Boerboel

SEX

Female

AGE

8 Months

INTERPRETED BY

Sebastian Schaub, DVM
Dr. med. vet. DipECVDI

HOSPITAL NAME

Lac Ste. Anne
Veterinary Services

REFERRING VET

Dr. K. McIntosh

INVOICE

52637

DATE

6-28-22