



PATIENT PRESENTING CLINICAL SIGNS

Spitfire Livingston They were driving back from a dog show in OR yesterday. Stopped to potty all the dogs. When Karen was walking the last dog she noticed it had some spear grass on him. 4 hours after stop, Spitfire started coughing on the ride home. he has continued to do so since arriving back home. Sounds like he is trying to clear his throat. She is worried he possibly inhaled some spear grass. Cough is worse with activity He did eat last night but not nearly as vigorous as he usually does. His energy was much more decreased as well when they arrived home last night. He seemed a little pale this morning, did eat his breakfast. Possibly vomited a little water this morning Front legs have yellow staining on them. Not sure if it was from urine or not. There was nothing in his crate.

SPECIES Canine

BREED Abnormal PE/Chem/CBC/UA Results: cough elicited with tracheal palpation decreased lung sounds increased respiratory rate and effort

Brittany Spaniel RADIOGRAPHIC STUDY OF THE THORAX

Radiographs of the thorax in three imaging planes are provided for review.

SEX RADIOGRAPHIC FINDINGS

Male The surrounding bony structures are within normal limits.

AGE The extrathoracic soft tissues present homogeneous without abnormalities.

2 Years, 11 Months The heart is of normal size and shape, there is no evidence of cardiac chamber or vascular enlargement.

INTERPRETED BY The cranial mediastinum presents the expected soft tissue opacity. The mediastinal width is less than twice the width of the vertebral column at the same level.

Sebastian Schaub, DVM
Dr. med. vet. DipECVDI

The trachea is normal in diameter and presents the anticipated course. The luminal outline of the trachea is smooth.

HOSPITAL NAME The ventral dependent aspects of the right cranial & middle lung lobe and the caudal part of the left cranial lung lobe present ventrally distributed consolidation of the lung parenchyma with air-bronchograms. The volume of the consolidated regions of the lung is maintained to mildly increased. The right caudal lung lobe has a significant ground glass opacity, effacing the pulmonary vasculature. The left caudal lung lobe is aerated and presents the expected architecture.

Elizabeth Animal Hospital

The diaphragm is well delineated with even surface and the expected mild cranial bulging of the diaphragmatic cupola.

REFERRING VET RADIOGRAPHIC DIAGNOSIS

Kim Allyn, DVM

- Ventrally distributed alveolar pattern and significant unstructured interstitial pattern right caudal lung lobe

INVOICE INTERPRETATION OF THE FINDINGS & FURTHER RECOMMENDATIONS

59042 The appreciated changes of the lung parenchyma are suggestive for (bacterial) pneumonia. Differentials can include pulmonary hemorrhage (either due to trauma, coagulopathy or lung worm infection), aspirated foreign body – commonly only one lobe is affected, but exudate may accumulate in the ventral dependent aspects of the lung – mycotic pneumonia (would expected accompanying lymphadenopathy). The odds for malignant origin are low. If not done so yet, recommend complementing workup by complete blood work to screen for inflammatory changes (e.g. leukocytosis, increase crp), supporting the diagnosis.

DATE 6-27-23



PATIENT

Spitfire Livingston

SPECIES

Canine

BREED

Brittany Spaniel

SEX

Male

AGE

2 Years, 11 Months

INTERPRETED BY

Sebastian Schaub, DVM
Dr. med. vet. DipECVDI

HOSPITAL NAME

Elizabeth Animal
Hospital

REFERRING VET

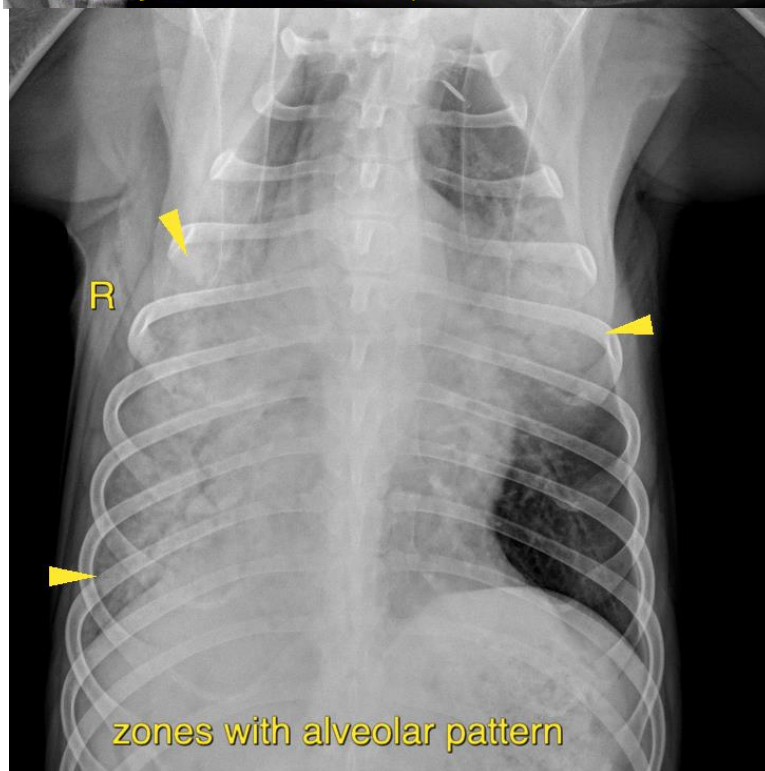
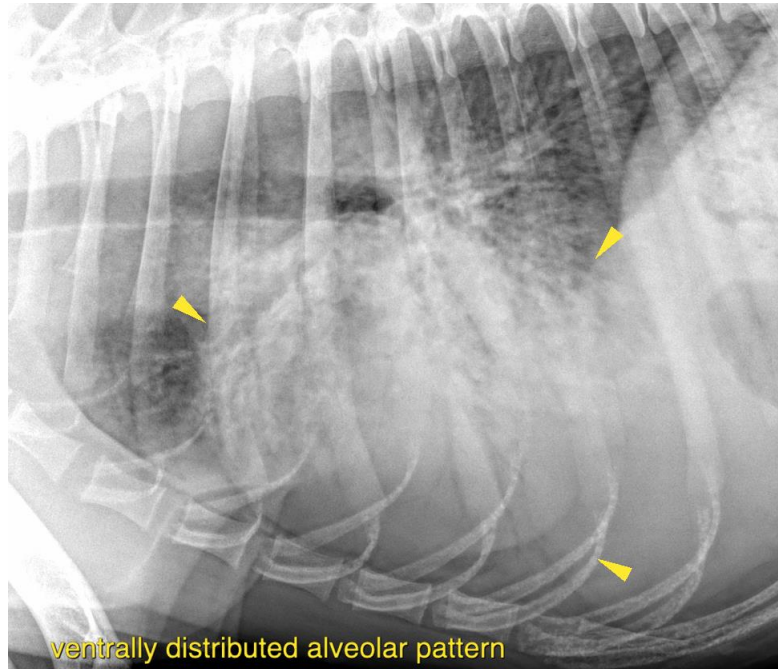
Kim Allyn, DVM

INVOICE

59042

DATE

6-27-23





PATIENT

Spitfire Livingston

SPECIES

Canine

The information and recommendations provided are based on the images presented by the referring veterinarian/sonographer. No evaluation can be communicated regarding pathology that was not visible in the image/video clips provided.

BREED

Brittany Spaniel

Thank you for this referral. If the clinical or image interpretation does not parallel your findings or if I can be of any further assistance please contact me.

SEX

Male

Sebastian Schaub, Sebastian Schaub, DVM, Dr. med. vet. DipECVDI
info@sonopath.com

AGE

2 Years, 11 Months

INTERPRETED BY

Sebastian Schaub, DVM
Dr. med. vet. DipECVDI

HOSPITAL NAME

Elizabeth Animal
Hospital

REFERRING VET

Kim Allyn, DVM

INVOICE

59042

DATE

6-27-23