



**PATIENT PRESENTING CLINICAL SIGNS**

**Freddy Spagnola/Gordnick** 8 yr old mixb- presenting with atopic dermatitis and progressive hindlimb pain/weakness. decreased CP defecits both hind legs. some discomfort along spinal and hip extension. we are starting an NSAID today and will soon start Adequan injections.

**SPECIES RADIOGRAPHIC STUDY OF THE LUMBAR SPINE AND PELVIS**

**Canine** A full set of radiographs of the lumbar spine and the pelvis is provided for review.

**RADIOGRAPHIC FINDINGS**

**BREED** Multifocal spondylosis formation is seen along the thoracic lumbar spine.

**Mix** The intervertebral disc space L1/L2 is narrowed.

Mineralized material is superimposed on the neuroforamina L1/L2 and L3/L4.

**SEX** The osseous and surrounding soft tissue structures of the pelvis are within normal limits. Both coxofemoral joints present mild incongruent joint space. The center of the femoral heads is level with the dorsal acetabular rim.

**MN**

**RADIOGRAPHIC DIAGNOSIS**

**AGE**

8 Years

- Discopathy L1/L2
- Mineralized material superimposed on neuroforamina L1/L2 and L3/L4
- Bilateral mild hip dysplasia
- Spondylosis deformans

**INTERPRETED BY**

Sebastian Schaub, DVM  
Dr. med. vet. DipECVDI

**INTERPRETATION OF THE FINDINGS & FURTHER RECOMMENDATIONS**

The mineralized material superimposed on the neuroforamina L1/L2 and L3/L4 can present mineralized disc material protruding into the vertebral canal or is a sequela to lateral spondylosis formation.

**HOSPITAL NAME**

Tenafly Vet Center

**REFERRING VET**

Marcela Salas

**INVOICE**

59026

**DATE**

6-27-23



**PATIENT**

Freddy  
Spagnola/Gordnick

**SPECIES**

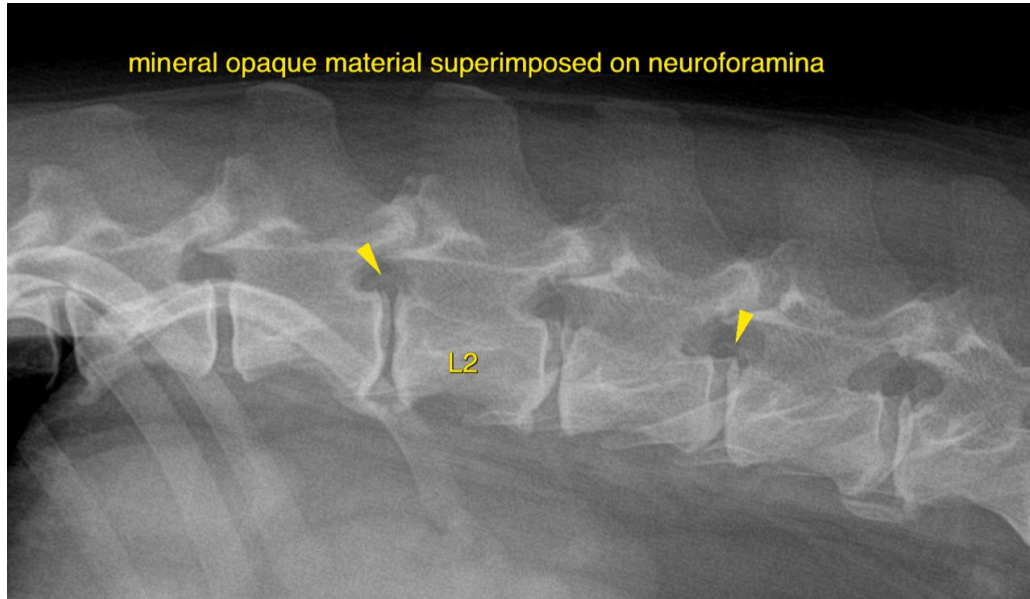
Canine

**BREED**

Mix

**SEX**

MN



**AGE**

8 Years

**INTERPRETED BY**

Sebastian Schaub, DVM  
Dr. med. vet. DipECVDI

The information and recommendations provided are based on the images presented by the referring veterinarian/sonographer. No evaluation can be communicated regarding pathology that was not visible in the image/video clips provided.

Thank you for this referral. If the clinical or image interpretation does not parallel your findings or if I can be of any further assistance please contact me.

**HOSPITAL NAME**

Tenafly Vet Center

Sebastian Schaub, Sebastian Schaub, DVM, Dr. med. vet. DipECVDI  
[info@sonopath.com](mailto:info@sonopath.com)

**REFERRING VET**

Marcela Salas

**INVOICE**

59026

**DATE**

6-27-23