



PATIENT

Terra Mann

SPECIES

Feline

BREED

DSH

SEX

F

AGE

12 Years

INTERPRETED BY

Sebastian Schaub, DVM
Dr. med. vet. DipECVDI

HOSPITAL NAME

Truscott Animal
Hospital

REFERRING VET

Dr. Medhat Meawad

INVOICE

52592

DATE

6-27-22

PRESENTING CLINICAL SIGNS

Terra presented to us with swelling in the left nasal septum extending from the left eye to the left nostril. Swelling is soft on palpation. R/O abscess vs tumor vs other
Abnormal PE/Chem/CBC/UA Results: Pink eye discharge OS. No stain uptake with fluorescein stain. Reddish left nasal discharge. No neuro deficit. No LNs enlargement. WBC and platelets WNL

RADIOGRAPHIC STUDY OF THE SKULL

Radiographs of the skull in multiple imaging planes are provided for review.

RADIOGRAPHIC FINDINGS

A homogeneous moderate soft tissue swelling is appreciated at the left dorsal and lateral aspect of the nose. In the oblique projection of the skull, mild immature periosteal new bone formation is appreciated at the dorsal aspect of the osseous lining of the nasal cavity.

No overt opacification of the nasal cavity is appreciated.

The tympanic bullae are aerated and present a smooth osseous lining.

RADIOGRAPHIC DIAGNOSIS

- Soft tissue swelling left dorsolateral aspect of nose with mild periosteal new bone formation

INTERPRETATION OF THE FINDINGS & FURTHER RECOMMENDATIONS

The subcutaneous soft tissue swelling in combination with the periosteal new bone formation is not specific and inflammatory as well as neoplastic origin need to be considered. There are no overt signs for osteolysis or large nasal mass. Recommend FNA sampling of the subcutaneous soft tissue swelling as advanced diagnostic tool. A CT study of the skull can be used for further assessment of the extend of swelling and ruling out small osteolytic lesions.



PATIENT

Terra Mann

SPECIES

Feline

BREED

DSH

SEX

F

AGE

12 Years

INTERPRETED BY

Sebastian Schaub, DVM
Dr. med. vet. DipECVDI

HOSPITAL NAME

Truscott Animal
Hospital

REFERRING VET

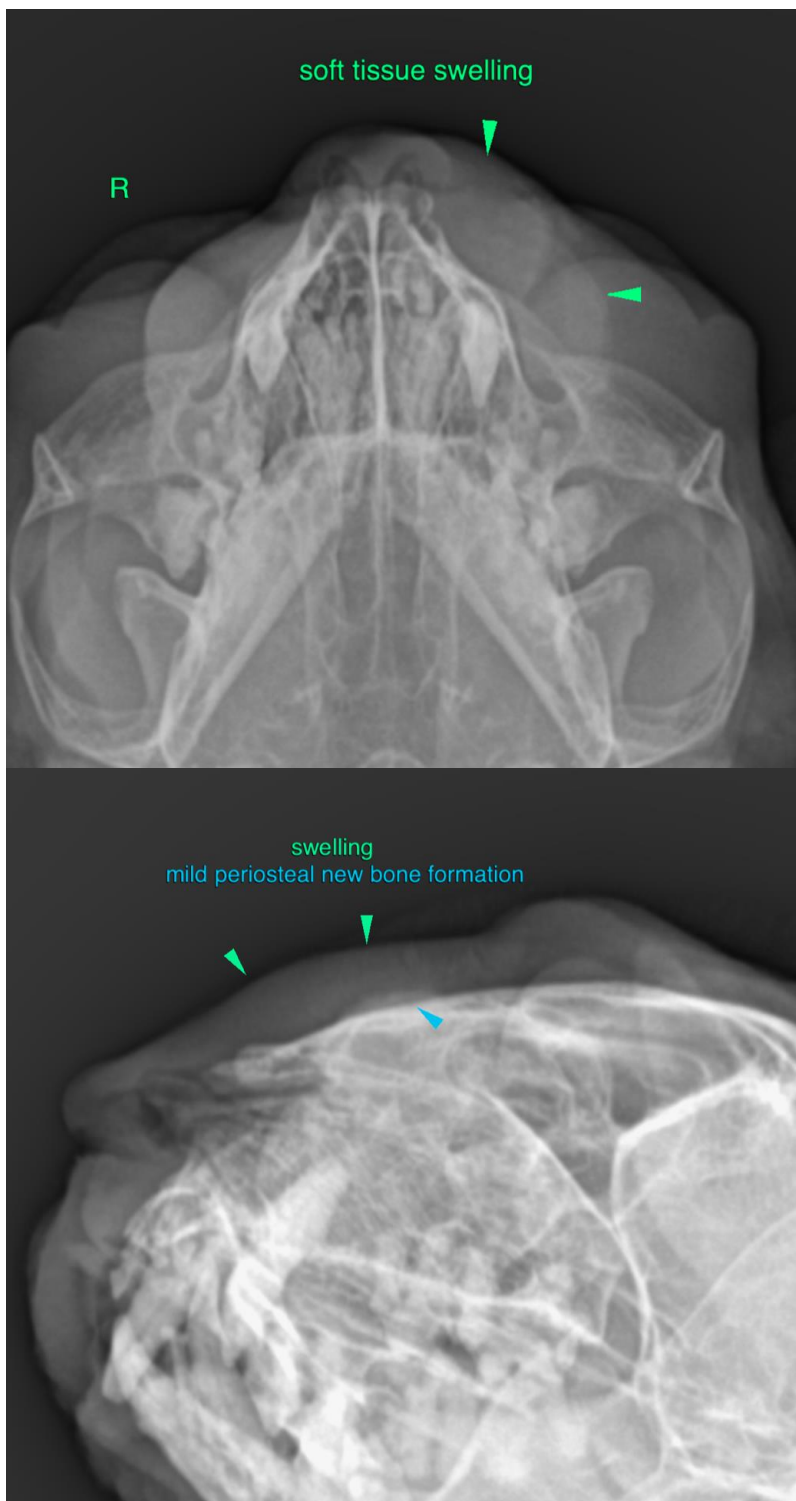
Dr. Medhat Meawad

INVOICE

52592

DATE

6-27-22





PATIENT

Terra Mann

SPECIES

Feline

The information and recommendations provided are based on the images presented by the referring veterinarian/sonographer. No evaluation can be communicated regarding pathology that was not visible in the image/video clips provided.

BREED

DSH

Thank you for this referral. If the clinical or image interpretation does not parallel your findings or if I can be of any further assistance please contact me.

Sebastian Schaub, Sebastian Schaub, DVM, Dr. med. vet. DipECVDI
sebast.schaub@gmail.com

SEX

F

AGE

12 Years

INTERPRETED BY

Sebastian Schaub, DVM
Dr. med. vet. DipECVDI

HOSPITAL NAME

Truscott Animal
Hospital

REFERRING VET

Dr. Medhat Meawad

INVOICE

52592

DATE

6-27-22