



PATIENT

Delilah Mayer

PRESENTING CLINICAL SIGNS

16yo cat, seemed wobbling standing up since last night, didn't eat last night, didn't leave her bed last night. Still using litter, poop is dry and red. Not sure if blood or something she ate.
Abnormal PE/Chem/CBC/UA Results: mild elevation in SDMA mild elevation in globulins mild neutropenia

SPECIES

Feline

RADIOGRAPHIC STUDY OF THE PELVIS

Radiographs of the pelvis in two orthogonal imaging planes are provided for review.

BREED

DSH

RADIOGRAPHIC FINDINGS

A spaghetti sign is appreciated at the caudal aspect of the spleen.

The osseous and surrounding soft tissue structures of the pelvis are within normal limits. Both coxofemoral joints present smooth osseous margins and congruent joint spaces.

SEX

FS

RADIOGRAPHIC DIAGNOSIS

- Suspect acquired portosystemic shunts – spleno-gonadal shunt
- Normal pelvis and coxofemoral joints

AGE

16 Years

INTERPRETATION OF THE FINDINGS & FURTHER RECOMMENDATIONS

The radiographic study of the pelvis presents without abnormalities. Check clinically for normal pulse/blood pressure in both hind limbs and rule out clinical signs originating from the spine as well.

The spaghetti sign is suggestive for incidental acquired portosystemic shunting – which is considered as a sequela to neutering and is commonly not associated with clinical signs.

INTERPRETED BY

Sebastian Schaub, DVM
Dr. med. vet. DipECVDI

HOSPITAL NAME

Balmy Beach Pet
Hospital

REFERRING VET

Dr. Singh

INVOICE

52596

DATE

6-27-22



PATIENT

Delilah Mayer

SPECIES

Feline

BREED

DSH

SEX

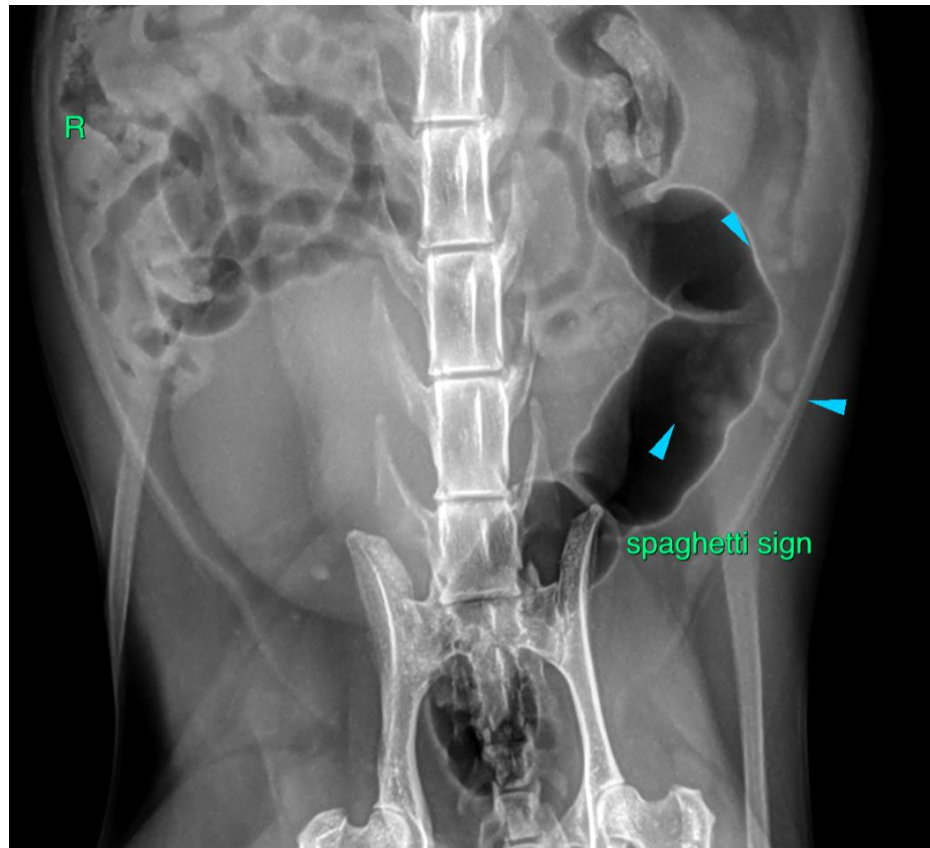
FS

AGE

16 Years

INTERPRETED BY

Sebastian Schaub, DVM
Dr. med. vet. DipECVDI



HOSPITAL NAME

Balmy Beach Pet
Hospital

REFERRING VET

Dr. Singh

INVOICE

52596

DATE

6-27-22

The information and recommendations provided are based on the images presented by the referring veterinarian/sonographer. No evaluation can be communicated regarding pathology that was not visible in the image/video clips provided.

Thank you for this referral. If the clinical or image interpretation does not parallel your findings or if I can be of any further assistance please contact me.

Sebastian Schaub, Sebastian Schaub, DVM, Dr. med. vet. DipECVDI
sebast.schaub@gmail.com