

**PATIENT PRESENTING CLINICAL SIGNS**

Max Deur Was ran over by a tractor May 30, 2023 and was seen at emerg. Rads were taken and pelvic fracture was diagnosed. Patient was prescribed meloxicam, gabapentin, and strict rest recommended today. Client came in today wanting to know if pelvis fracture is healed and dog can return to work. Dog has been moving good, no signs of pain. Was sedated and pelvic rads taken.

SPECIES

Canine

Abnormal PE/Chem/CBC/UA Results: Dog is aggressive, tried to bite when we were reaching for back end (checking to see if 2 testicles), was muzzled for remainder of exam. NSF on PE. No lameness, stiffness, or pain appreciated today when he was moving.

BREED

Border Collie

RADIOGRAPHIC STUDY OF THE PELVIS

Radiographs of the pelvis in orthogonal imaging planes are provided for review.

RADIOGRAPHIC FINDINGS**SEX**

Intact Male

A transverse fracture line is seen in the ramus of the pubic bone bilaterally as well as a fracture line along the craniomedial margin of the ischiatic table, the fracture lines are rounded. The pelvic floor is deviated craniodorsally. Both coxofemoral joints present smooth osseous margins and congruent joint spaces.

AGE

3.5 Years

RADIOGRAPHIC DIAGNOSIS

- Chronic fractures of the pelvic floor with mild craniodorsal displacement of the pelvic floor

INTERPRETED BY

Sebastian Schaub, DVM
Dr. med. vet. DipECVDI

INTERPRETATION OF THE FINDINGS & FURTHER RECOMMENDATIONS

The radiographic changes are fitting the history. The fractures of the pelvic floor present rounded margins, due to the chronicity. No mineralized callus formation is appreciated, however fracture healing may be achieved only by fibrous tissue without mineralized callus formation. As the pelvic ring is intact and the patient does not present signs of pain, gradually increasing exercise over the next two weeks up to normal exercise is considered beneficial.

HOSPITAL NAME

Nagel & Co.
Veterinary Services

REFERRING VET

Dr. Jordan Steedman

INVOICE

59010

DATE

6-26-23



PATIENT

Max Deur

SPECIES

Canine

BREED

Border Collie

SEX

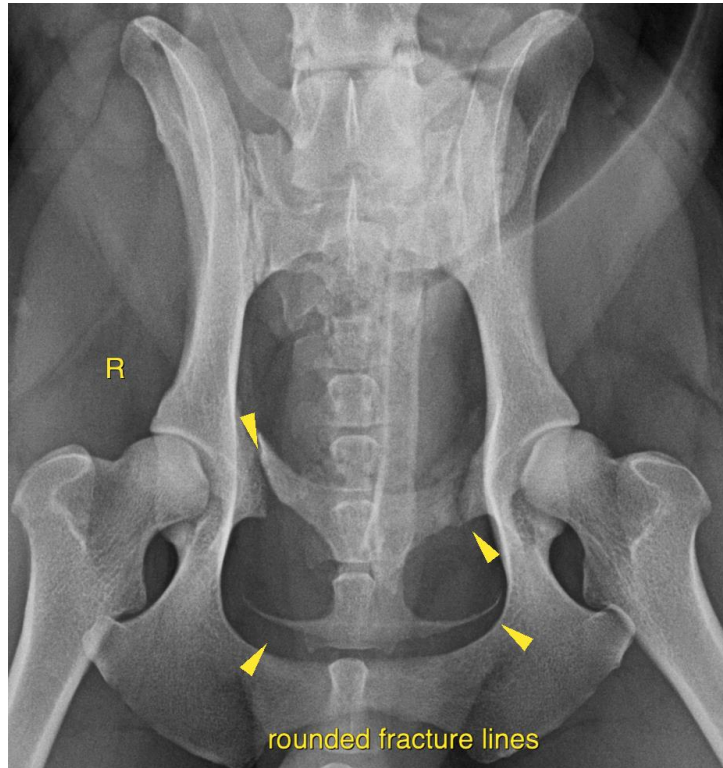
Intact Male

AGE

3.5 Years

INTERPRETED BY

Sebastian Schaub, DVM
Dr. med. vet. DipECVDI



HOSPITAL NAME

Nagel & Co.
Veterinary Services

The information and recommendations provided are based on the images presented by the referring veterinarian/sonographer. No evaluation can be communicated regarding pathology that was not visible in the image/video clips provided.

REFERRING VET

Dr. Jordan Steedman

Thank you for this referral. If the clinical or image interpretation does not parallel your findings or if I can be of any further assistance please contact me.

Sebastian Schaub, Sebastian Schaub, DVM, Dr. med. vet. DipECVDI
info@sonopath.com

INVOICE

59010

DATE

6-26-23