



PATIENT PRESENTING CLINICAL SIGNS

Kodama Sters History: Scratching at ears and shaking head. No history of otitis, will flush ears twice monthly with otic flush. Occasionally stumbling/disoriented with mildly ataxic gait, no obvious head tilt. Ongoing sneezing and nasal discharge.

SPECIES

Canine Abnormal PE/Chem/CBC/UA Results: Tympanic membrane not visualized AU, fluid present in horizontal canal AD.

BREED

American Bully A high resolution pre- and post-contrast CT study of the skull is provided for review.

COMPUTED TOMOGRAPHIC FINDINGS

SEX

Intact Male The pictured parts of the dentition are complete and unremarkable in all jaw quadrants.

The nasal cavity presents the expected aerated spaces between thin & even conchae and turbinates with smooth mucosal lining.

AGE

3 Years Both temporomandibular joints present congruent joint spaces with even subchondral bone surfaces and are considered within normal limits.

Both tympanic bullae are filled with soft tissue attenuating material and the osseous lining is moderately thickened bilaterally. The external ear canals are within normal limits.

INTERPRETED BY

Sebastian Schaub, DVM Dr. med. vet. DipECVDI The submandibular and medial retropharyngeal lymph nodes are small and elongated with a normal short-to-long-axis-ratio is < 0.5, the attenuation is uniform.

COMPUTED TOMOGRAPHIC DIAGNOSIS

HOSPITAL NAME

Healing Spirit AH

- Bilateral chronic otitis media
- Normal upper airways

INTERPRETATION OF THE FINDINGS & FURTHER RECOMMENDATIONS

REFERRING VET

Dr. Desen Ertunc The main finding is the bilateral otitis media that can be a source for vestibular disease that might be a cause for ataxia.

INVOICE

16317

DATE

6/24/22

No abnormalities of the upper airways are appreciated, explaining the sneezing/nasal discharge. To screen for non-specific rhinitis (e.g. lymphocytic plasmocytic, eosinophilic), rhinoscopy including biopsy might be beneficial.



PATIENT

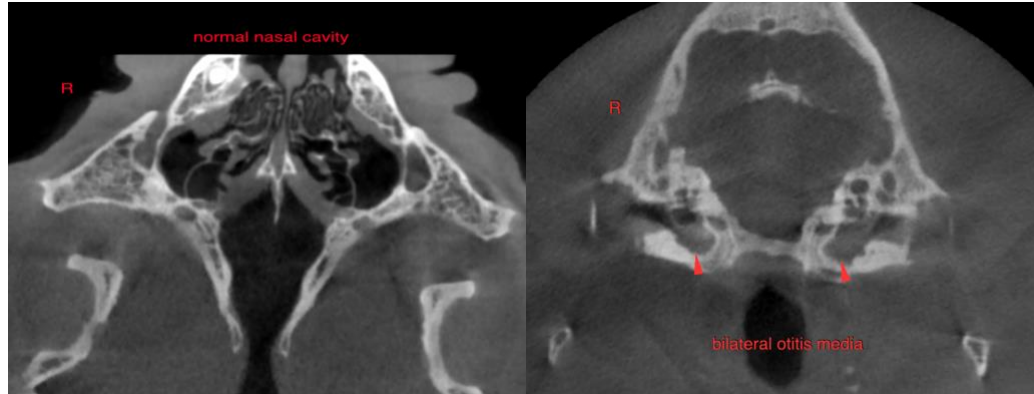
Kodama Sters

SPECIES

Canine

BREED

American Bully



SEX

Intact Male

AGE

3 Years

The information and recommendations provided are based on the images presented by the referring veterinarian/sonographer. No evaluation can be communicated regarding pathology that was not visible in the image/video clips provided.

Thank you for this referral. If the clinical or image interpretation does not parallel your findings or if I can be of any further assistance please contact me.

Sebastian Schaub, Sebastian Schaub, DVM, Dr. med. vet. DipECVDI
sebast.schaub@gmail.com

INTERPRETED BY

Sebastian Schaub,
DVM Dr. med. vet.
DipECVDI

HOSPITAL NAME

Healing Spirit AH

REFERRING VET

Dr. Desen Ertunc

INVOICE

16317

DATE

6/24/22