



PATIENT

Diesel Ristic

PRESENTING CLINICAL SIGNS

History of mass in the abdomen and heavy breathing/panting. Please check previous x-ray from February- we noticed in physical exam that the mass in the abdomen may have increased in size- also noticed a possible mass in shoulder region Muffled heart sound with possible mass in chest r/o pulmonary metastasis and pericardial perfusion

SPECIES

Canine

RADIOGRAPHIC STUDY OF THE THORAX AND ABDOMEN

A complete set of radiographs of the thorax and abdomen is provided for review.

BREED

German Shepherd

RADIOGRAPHIC FINDINGS

Thorax

Multifocal mild spondylosis formation is seen along the thoracic spine.

SEX

Neutered Male

The extrathoracic soft tissues present homogeneous without abnormalities.

The cardiac silhouette is significantly enlarged and rounded – presenting a globoid shape.

A increased soft tissue opacification of the cranioventral mediastinum is appreciated.

AGE

11 Years

A moderate amount of soft tissue material is appreciated in the pleural cavity and the lung lobes are retracted from the thoracic wall and the margins are rounded.

Multifocal throughout the lung parenchyma,, well-defined, soft tissue opaque nodular lesions are appreciated.

INTERPRETED BY

Sebastian Schaub, DVM
Dr. med. vet. DipECVDI

The diaphragm is well delineated with even surface and the expected mild cranial bulging of the diaphragmatic cupola.

Abdomen

HOSPITAL NAME

Truscott Animal
Hospital

In the cranial abdomen, ventral to the pylorus, a well-defined roundish mass, measuring 5 cm in diameter is appreciated – seen at the cranial margin of the spleen in the VD projection.

Two small nodular lesions are appreciated at the caudoventral hepatic margins.

The hepatic volume is moderately increased the liver is protruding beyond the costal arch; the gastric axis is deviated caudally. The caudoventral hepatic margins are rounded.

REFERRING VET

Dr. Medhat Meawad

The prostate is prominent and presents mild mineralization.

Mild fat-stranding of the peritoneal fat is appreciated.

INVOICE

52577

RADIOGRAPHIC DIAGNOSIS

- Marked enlargement of the cardiac silhouette with globoid shape
- Possible cranial mediastinal lymphadenopathy or cranioventral mediastinal mass
- Structured nodular interstitial lung pattern
- Suspect mild pleural effusion
- Hepatomegaly with nodular lesions at the caudal margins
- Prostatomegaly with dystrophic mineralization
- Suspect mild peritoneal effusion

DATE

6-24-22



PATIENT

Diesel Ristic

- Nodular mass region of the spleen
- Spondylosis deformans

INTERPRETATION OF THE FINDINGS & FURTHER RECOMMENDATIONS

SPECIES

Canine

The significant cardiomegaly is highly suggestive for pericardial effusion and in combination with the structured nodular lung pattern, underlying neoplastic disease is considered likely here. The increased soft tissue opacification of the cranial mediastinum might be a sequela to the pleural effusion or presents a mediastinal mass.

BREED

German Shepherd

The top differential for the prominent prostate with dystrophic mineralization is neoplastic transformation with carcinoma being most likely.

Potentials for the hepatomegaly include metabolic hepatic disease/steroid induced hepatopathy, hepatitis or neoplastic infiltration. The latter is considered most likely here.

SEX

Neutered Male

The nodular lesion in the region of the spleen can be a sequela to metastasis, primary neoplasia or nodular hyperplasia.

A cardiac echo might be used to confirm the diagnosis of pericardial effusion and checking for potential mass.

AGE

11 Years

Overall, the prognosis is considered poor to infaust.

INTERPRETED BY

Sebastian Schaub, DVM
Dr. med. vet. DipECVDI

HOSPITAL NAME

Truscott Animal
Hospital

REFERRING VET

Dr. Medhat Meawad

INVOICE

52577

DATE

6-24-22



PATIENT

Diesel Ristic

SPECIES

Canine

BREED

German Shepherd

SEX

Neutered Male

AGE

11 Years

INTERPRETED BY

Sebastian Schaub, DVM
Dr. med. vet. DipECVDI

HOSPITAL NAME

Truscott Animal
Hospital

REFERRING VET

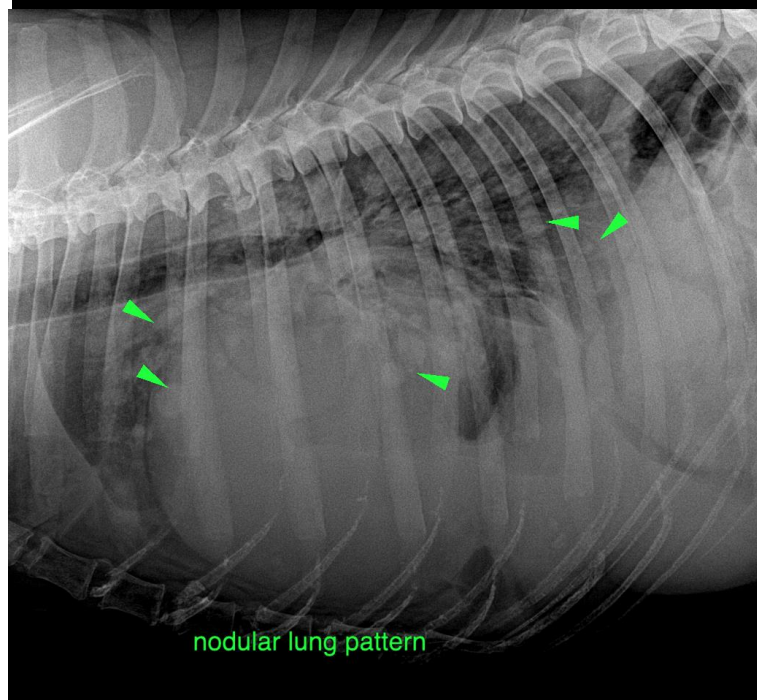
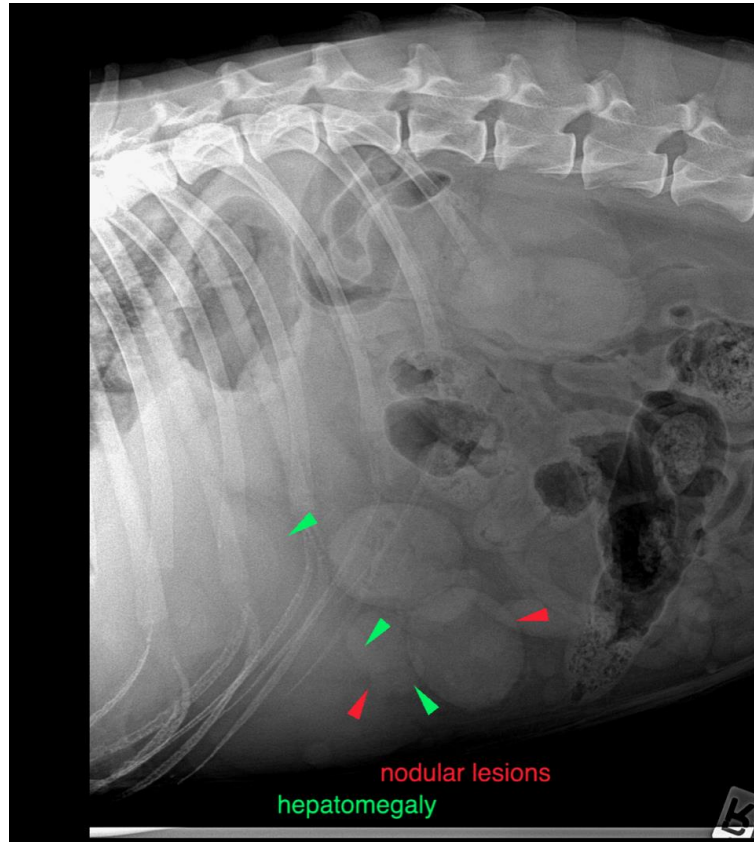
Dr. Medhat Meawad

INVOICE

52577

DATE

6-24-22





PATIENT

Diesel Ristic

SPECIES

Canine

BREED

German Shepherd

SEX

Neutered Male

AGE

11 Years

INTERPRETED BY

Sebastian Schaub, DVM
Dr. med. vet. DipECVDI

HOSPITAL NAME

Truscott Animal
Hospital

REFERRING VET

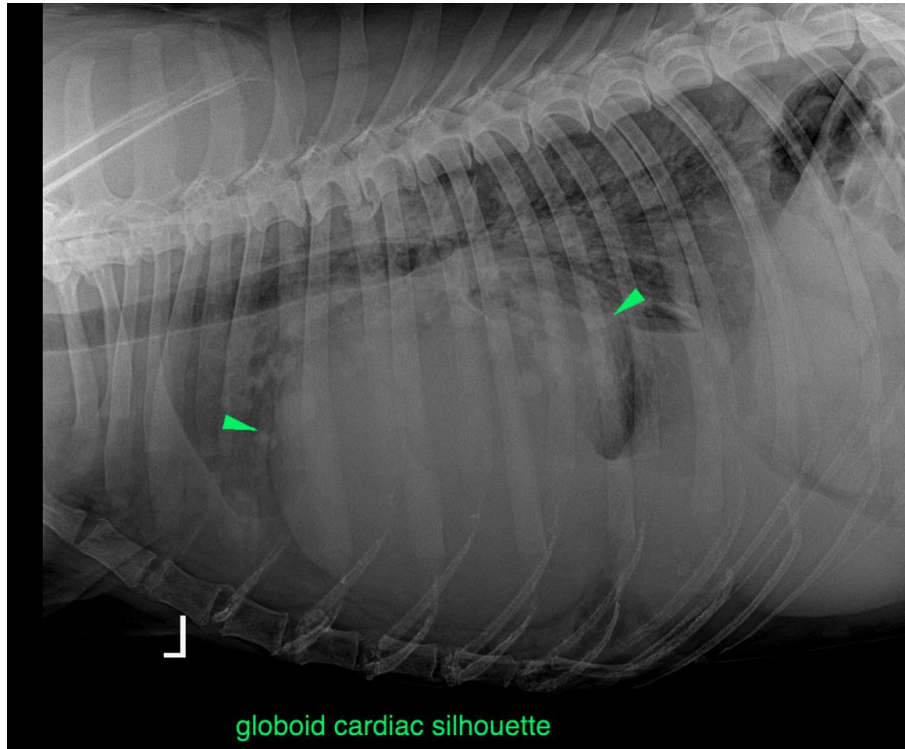
Dr. Medhat Meawad

INVOICE

52577

DATE

6-24-22



The information and recommendations provided are based on the images presented by the referring veterinarian/sonographer. No evaluation can be communicated regarding pathology that was not visible in the image/video clips provided.

Thank you for this referral. If the clinical or image interpretation does not parallel your findings or if I can be of any further assistance please contact me.

Sebastian Schaub, Sebastian Schaub, DVM, Dr. med. vet. DipECVDI
sebast.schaub@gmail.com