



PATIENT PRESENTING CLINICAL SIGNS

Chloe Moran History: Historical cough that is worsening with increased respiratory changes at home. Historical AA luxation repair. Examination - crackles noted right side with increase upper airway 'wet sounds'. No murmurs appreciated.

SPECIES RADIOGRAPHIC STUDY OF THE THORAX

Canine Radiographs of the thorax in three imaging planes are provided for review.

BREED RADIOGRAPHIC FINDINGS

Yorkie Two surgical pins are appreciated within the ventral aspect of the atlas and axis – history of surgical atlantoaxial instability stabilization.

SEX The extrathoracic soft tissues present homogeneous without abnormalities.

Spayed Female The heart is of normal size and shape, there is no evidence of cardiac chamber or vascular enlargement. The pulmonary vasculature is within normal limits.

AGE The cranial mediastinum presents the expected soft tissue opacity. The mediastinal width is less than twice the width of the vertebral column at the same level.

11.10 Years A soft tissue membrane is bulging ventrally into the tracheal lumen of the cervical segment.

INTERPRETED BY The bronchial tree presents with thin walls and tapers uniformly towards the periphery as expected. The lung parenchyma presents the expected architecture and opacity; the intrapulmonary vascular branching is seen up to the third order lung vessels.

Sebastian Schaub,
DVM Dr. med. vet.
DipECVDI

The diaphragm is well delineated with even surface and the expected mild cranial bulging of the diaphragmatic cupola.

HOSPITAL NAME

Incline VH

RADIOGRAPHIC DIAGNOSIS

- Suspect redundant tracheal membrane

REFERRING VET

Dr. Mulchi

INTERPRETATION OF THE FINDINGS & FURTHER RECOMMENDATIONS

The radiographic study of the thorax presents without clinically relevant abnormalities. The subjective prominent cardiac silhouette is considered as a sequela to the thoracic conformation.

INVOICE

16320

Be aware that negative thoracic radiographs do not rule out tracheitis or bronchitis and underlying inflammatory lower airway disease is still a potential for the history of cough.

DATE

6/24/22



PATIENT A redundant tracheal membrane can be a precursor for tracheal collapse, but at this point the clinical relevance is questionable.

Chloe Moran

TECHNICAL COMMENTS

SPECIES Human fingers are seen in the primary beam, please consider radiation safety guidelines!

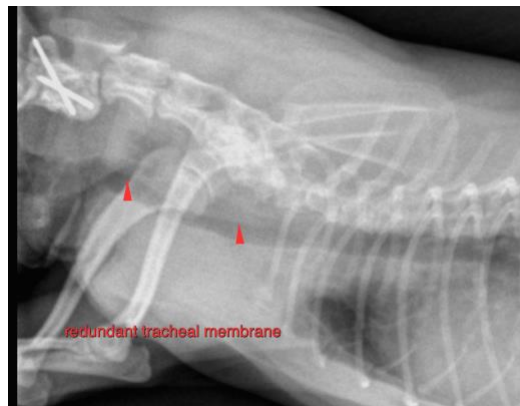
Canine

BREED

Yorkie

SEX

Spayed Female



AGE

11.10 Years

The information and recommendations provided are based on the images presented by the referring veterinarian/sonographer. No evaluation can be communicated regarding pathology that was not visible in the image/video clips provided.

INTERPRETED BY

Sebastian Schaub,
DVM Dr. med. vet.
DipECVDI

Thank you for this referral. If the clinical or image interpretation does not parallel your findings or if I can be of any further assistance please contact me.

Sebastian Schaub, Sebastian Schaub, DVM, Dr. med. vet. DipECVDI
sebast.schaub@gmail.com

HOSPITAL NAME

Incline VH

REFERRING VET

Dr. Mulchi

INVOICE

16320

DATE

6/24/22