



PATIENT PRESENTING CLINICAL SIGNS

PATIENT Oban Cheatham
SPECIES History: Pt had a cyst removed below left eye along with a COHAT (removed 16 teeth) in April 2023 by rDVM. Has had issues with the left eye swelling since the procedure. Presented in clinic last night for the left side of his nose, and left eye swelling. Performed CT scan, COHAT, took biopsy and culture today. (please see attachments for rDVM records and today's in-house blood work).

Canine COMPUTED TOMOGRAPHIC STUDY OF THE SKULL

A high resolution pre- and post-contrast CT study of the skull is provided for review.

BREED COMPUTED TOMOGRAPHIC FINDINGS

BREED West Highland Terrier
 Triadan 105, 108-110, 208-210, 308, 311, 408 and 411 are absent.

SEX Along the right lateral aspect of the maxillary bone, an ill-defined soft tissue swelling is appreciated, extending from the level of the zygomatic bone rostrally up to the level of triadan 204. Post contrast administration, the subcutaneous swelling has a heterogeneous contrast enhancement pattern. An osseous involvement is not appreciated. The subcutaneous fat caudally along the left aspect of the skull presents edematous swelling.

AGE 9 Years 4 Months
 The nasal cavity presents the expected aerated spaces between thin & even conchae and turbinates with smooth mucosal lining.

INTERPRETED BY Both temporomandibular joints present congruent joint spaces with even subchondral bone surfaces and are considered within normal limits.

Sebastian Schaub, DVM Dr. med. vet. DipECVDI
 Both tympanic bullae are aerated, the mucosal lining is not seen, the bony wall is smooth and thin. The external ear canals are within normal limits.

HOSPITAL NAME The brain presents no deviation from normal anatomy and symmetry. The brain parenchyma is homogeneous and within normal limits for attenuation and distribution of contrast enhancement.
 Neel VH The ventricular system is non-dilated and symmetric.

The left mandibular lymph nodes and left medial retropharyngeal lymph node are prominent.

REFERRING VET COMPUTED TOMOGRAPHIC DIAGNOSIS

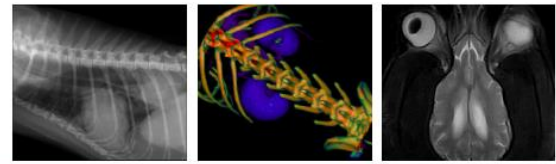
- Dr. Ellen Domnick
- Diffuse, heterogeneous contrast enhancing swelling along the left upper lip
 - Secondary edematous swelling left aspect of the skull
 - Lymphadenopathy ipsilateral mandibular and medial retropharyngeal lymph nodes
 - Multiple absent teeth

INVOICE
 23052

INTERPRETATION OF THE FINDINGS & FURTHER RECOMMENDATIONS

DATE

6/23/23



PATIENT

Oban Cheatham

The appreciated swelling along the left upper lip is not specific, however I would consider the odds for inflammatory origin higher than for neoplastic transformation – such as mast cell tumor. Biopsy and sampling for microbial culture has already been performed for further workup and results are pending.

SPECIES

Canine

BREED

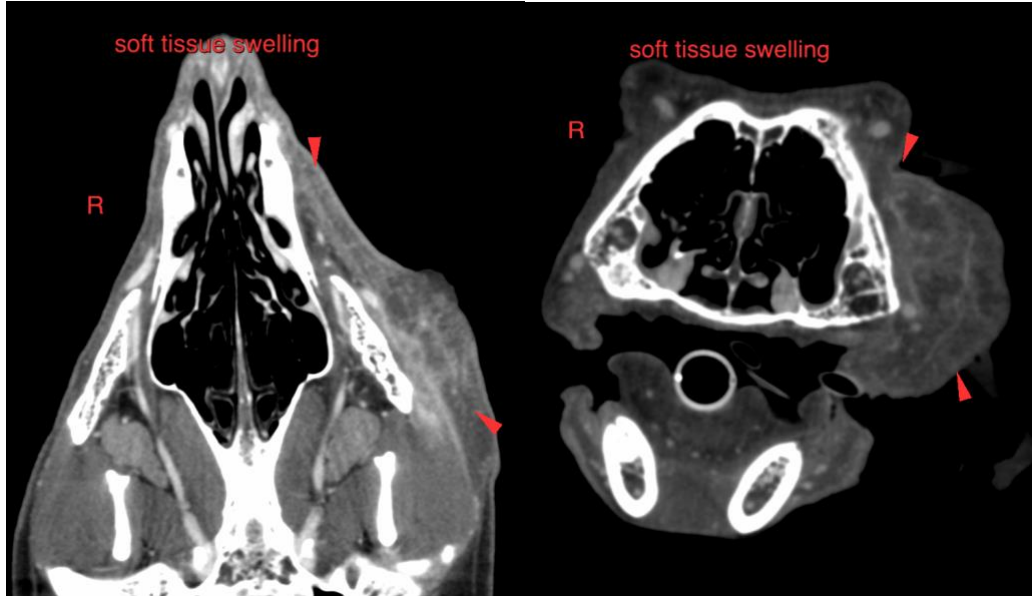
West Highland Terrier

SEX

Neutered Male

AGE

9 Years 4 Months



INTERPRETED BY

Sebastian Schaub,
DVM Dr. med. vet.
DipECVDI

The information and recommendations provided are based on the images presented by the referring veterinarian/sonographer. No evaluation can be communicated regarding pathology that was not visible in the image/video clips provided.

Thank you for this referral. If the clinical or image interpretation does not parallel your findings or if I can be of any further assistance please contact me.

HOSPITAL NAME

Neel VH

Sebastian Schaub, Sebastian Schaub, DVM, Dr. med. vet. DipECVDI
info@sonopath.com

REFERRING VET

Dr. Ellen Domnick

INVOICE

23052

DATE

6/23/23