



PATIENT PRESENTING CLINICAL SIGNS

Lily Roberts Coughing especially at night for almost 2 months, abdominal breathing on and off
 Abnormal PE/Chem/CBC/UA Results: Physical Exam findings include a grade 4-5 heart murmur, mild crackles heard cranially upon auscultation, and a tense abdomen. Blood work pending.

SPECIES RADIOGRAPHIC STUDY OF THE THORAX & ABDOMEN

Canine A complete set of radiographs of the thorax & abdomen is provided for review.

RADIOGRAPHIC FINDINGS

BREED The body condition score is 8-9/9.

Chihuahua Mix Thorax

The surrounding bony structures are within normal limits.

SEX The extrathoracic soft tissues present homogeneous without abnormalities.

Spayed Female The heart is of normal size and shape, there is no evidence of cardiac chamber or vascular enlargement. The pulmonary vasculature is within normal limits.

AGE The cranial mediastinum presents the expected soft tissue opacity. The mediastinal width is less than twice the width of the vertebral column at the same level.

8 Years The trachea is normal in diameter and presents the anticipated course. The luminal outline of the trachea is smooth.

INTERPRETED BY

The bronchial tree presents with thin walls and tapers uniformly towards the periphery as expected.

Sebastian Schaub, DVM
 Dr. med. vet. DipECVDI

The lung parenchyma presents the expected architecture and opacity; the intrapulmonary vascular branching is seen up to the third order lung vessels.

HOSPITAL NAME The diaphragm is well delineated with even surface and the expected mild cranial bulging of the diaphragmatic cupola.

Truscott Animal
 Hospital

Abdomen

The vertebral endplates L4/L5 present moderate spondylosis formation. Mineralized material is superimposed on the ventral aspect of the neuroforamina L4/L5.

REFERRING VET

Dr. Erini Abraham

No abnormalities of the extraabdominal soft tissues are noted. The abdominal wall is smooth and thin.

The serosal detail is maintained throughout the peritoneal and retroperitoneal space.

INVOICE

The hepatic volume is increased, the liver is protruding caudally beyond the costal arch and the caudoventral hepatic margins are rounded.

58990 The splenic head is in the anticipated position and within normal limits for size and opacity. The splenic body and tail are considered normal for position, size, shape and opacity.

DATE

6-23-23

Both kidneys are seen and present with normal size, shape, delineation and opacity. The urinary bladder is in its anticipated position. No radiopaque calculi are noted throughout the upper and lower urinary tract.

The stomach is in its anticipated position and presents normal content.



PATIENT The small intestinal loops are of even diameter and non-dilated, a small amount of gas is seen within the small intestinal loops and considered within normal limits.

Lily Roberts

The colon is seen in the expected position and presents with appropriate content.

SPECIES

Canine

RADIOGRAPHIC DIAGNOSIS

- Obesity
- Hepatomegaly
- Spondylosis deformans L4/L5

BREED

Chihuahua Mix

INTERPRETATION OF THE FINDINGS & FURTHER RECOMMENDATIONS

The radiographic study of the thorax presents without specific abnormalities, explaining the history of cough. However, a negative radiographic study does not rule out possible tracheitis/bronchitis. Obesity is also a known predisposing factor for cough.

SEX

Spayed Female

Potentials for the hepatomegaly include metabolic hepatic disease (considered most likely)/steroid induced hepatopathy, hepatitis or neoplastic infiltration. Ultrasound including FNA sampling can be used as minimally advanced diagnostic tests.

AGE

8 Years

INTERPRETED BY

Sebastian Schaub, DVM
Dr. med. vet. DipECVDI

HOSPITAL NAME

Truscott Animal
Hospital

REFERRING VET

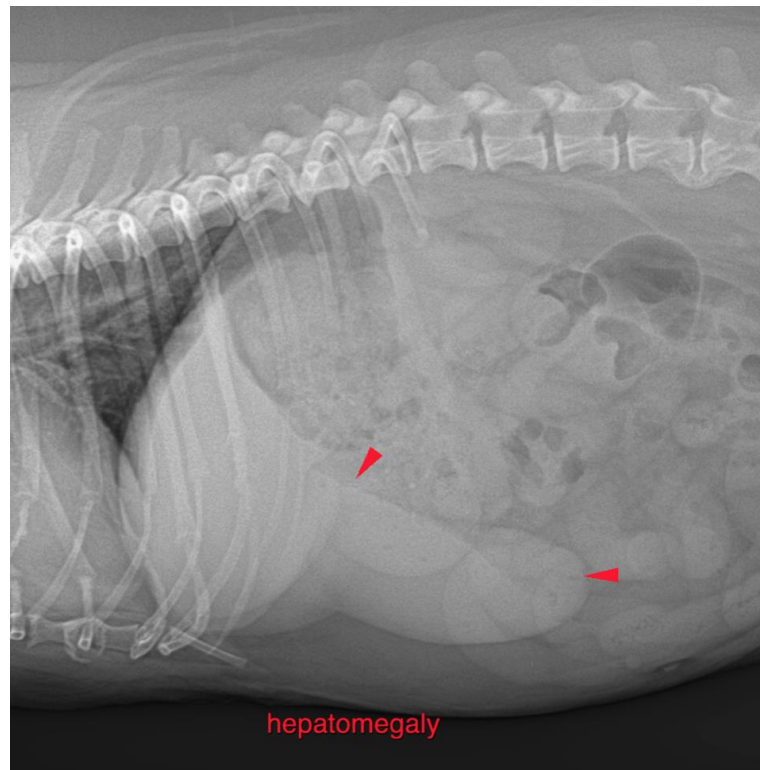
Dr. Erini Abraham

INVOICE

58990

DATE

6-23-23





PATIENT

Lily Roberts

The information and recommendations provided are based on the images presented by the referring veterinarian/sonographer. No evaluation can be communicated regarding pathology that was not visible in the image/video clips provided.

SPECIES

Canine

Thank you for this referral. If the clinical or image interpretation does not parallel your findings or if I can be of any further assistance please contact me.

BREED

Chihuahua Mix

Sebastian Schaub, Sebastian Schaub, DVM, Dr. med. vet. DipECVDI
info@sonopath.com

SEX

Spayed Female

AGE

8 Years

INTERPRETED BY

Sebastian Schaub, DVM
Dr. med. vet. DipECVDI

HOSPITAL NAME

Truscott Animal
Hospital

REFERRING VET

Dr. Erini Abraham

INVOICE

58990

DATE

6-23-23