



PATIENT PRESENTING CLINICAL SIGNS

Tesla Collins Presented to dentist due to chronic Right nasal discharge. Symptoms started after dental procedure. Abnormal PE/Chem/CBC/UA Results: Missing most teeth.

SPECIES COMPUTED TOMOGRAPHY OF THE SKULL

Feline A high resolution pre- and post-contrast CT study of the skull provided for review.

COMPUTED TOMOGRAPHIC FINDINGS

BREED All teeth but triadan 106, 303, 304, 308, 404 and 408 are absent. A retained root of triadan 108 is appreciated in the alveolar crest, the periodontal space is thin.

DSH In the right nasal cavity, advanced destruction of the nasal conchal & turbinate structures is appreciated, resulting in an empty nose of the right nasal cavity. A moderate amount of fluid attenuating material is attached to the nasal mucosal lining. The left nasal cavity is aerated and the conchal & turbinate structures.

SEX

Neutered Male Both temporomandibular joints present congruent joint spaces with even subchondral bone surfaces and are considered within normal limits.

AGE

9 Years Both tympanic bullae are aerated, the mucosal lining is not seen, the bony wall is smooth and thin. The external ear canals are within normal limits.

The brain presents no deviation from normal anatomy and symmetry. The brain parenchyma is homogeneous and within normal limits for attenuation and distribution of contrast enhancement. The ventricular system is non-dilated and symmetric.

INTERPRETED BY

The right mandibular and medial retropharyngeal lymph node are prominent.

Sebastian Schaub, DVM
Dr. med. vet. DipECVDI

COMPUTED TOMOGRAPHIC DIAGNOSIS

- Right sided destructive rhinitis
- Lymphadenopathy right mandibular and medial retropharyngeal lymph node
- Multiple absent teeth
- Retained fragment of a root of triadan 108 without signs of infection

HOSPITAL NAME

Mobile Pet Imaging

REFERRING VET

Meaux

INTERPRETATION OF THE FINDINGS & FURTHER RECOMMENDATIONS

An underlying cause for the right sided rhinitis is not appreciated, there is no evidence of oronasal fistula formation or dental abscess formation of the remaining dental element 106. Primary viral rhinitis ± bacterial superinfection or less likely mycotic rhinitis are considered most likely here. Rhinoscopy including sampling for microbial culture and histopathology can be used as advanced diagnostic test.

INVOICE

52575 Secondary reactive hyperplasia of the tributary lymph nodes.

DATE

6-23-22



PATIENT

Tesla Collins

SPECIES

Feline

BREED

DSH

SEX

Neutered Male

AGE

9 Years

INTERPRETED BY

Sebastian Schaub, DVM
Dr. med. vet. DipECVDI

HOSPITAL NAME

Mobile Pet Imaging

REFERRING VET

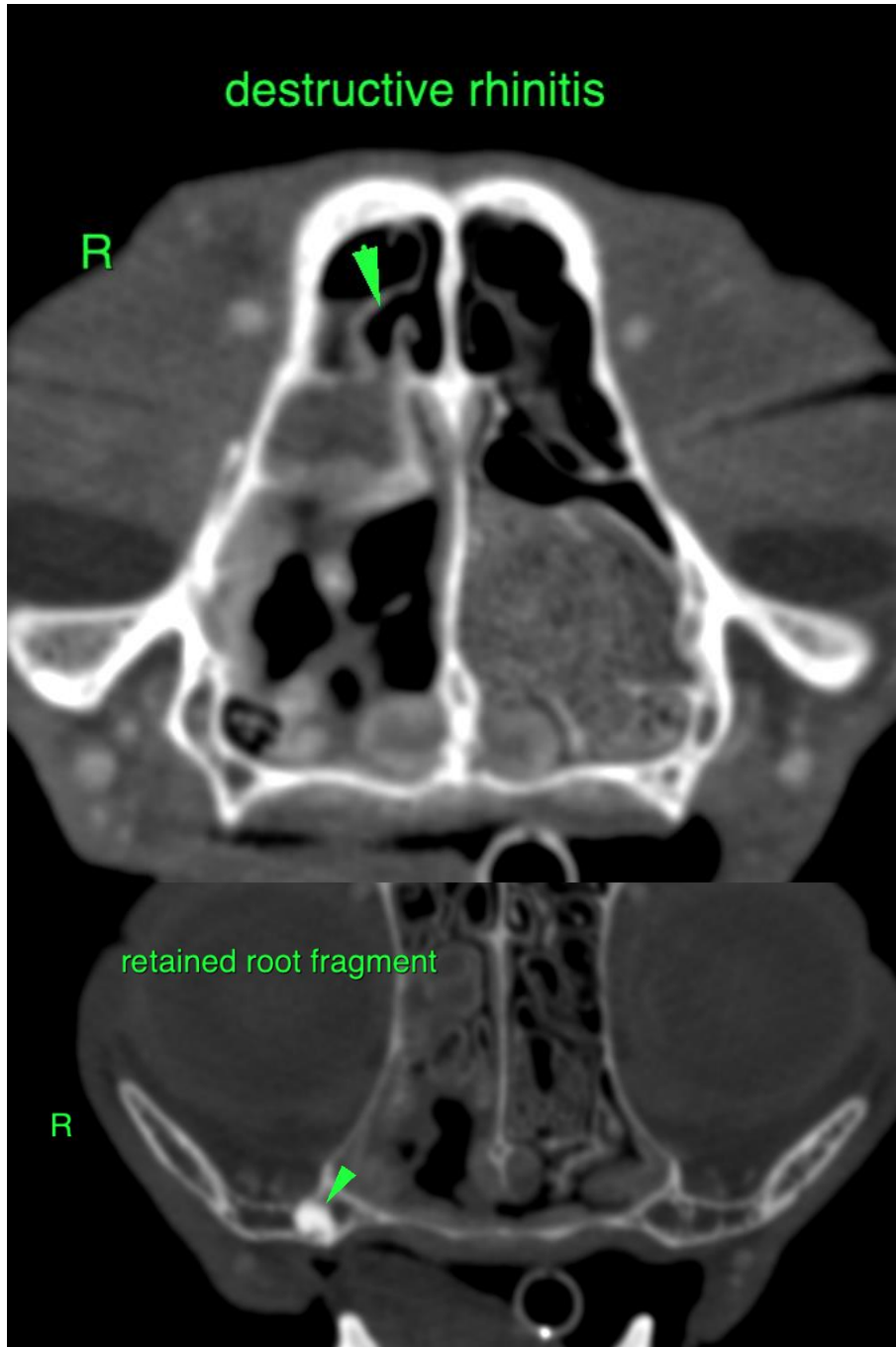
Meaux

INVOICE

52575

DATE

6-23-22



**PATIENT**

Tesla Collins

The information and recommendations provided are based on the images presented by the referring veterinarian/sonographer. No evaluation can be communicated regarding pathology that was not visible in the image/video clips provided.

SPECIES

Feline

Thank you for this referral. If the clinical or image interpretation does not parallel your findings or if I can be of any further assistance please contact me.

Sebastian Schaub, Sebastian Schaub, DVM, Dr. med. vet. DipECVDI
sebast.schaub@gmail.com

BREED

DSH

SEX

Neutered Male

AGE

9 Years

INTERPRETED BY

Sebastian Schaub, DVM
Dr. med. vet. DipECVDI

HOSPITAL NAME

Mobile Pet Imaging

REFERRING VET

Meaux

INVOICE

52575

DATE

6-23-22