



PATIENT PRESENTING CLINICAL SIGNS

Lance Edwards Acute onset of horner's syndrome in the left eye. ~1 month history of aural debris, shaking head, and scratching left ear.

SPECIES COMPUTED TOMOGRAPHY OF THE SKULL

Feline A pre- and post-contrast CT study of the skull in a bone and soft tissue reconstruction is provided for review.

BREED COMPUTED TOMOGRAPHIC FINDINGS

DLH Triadan 407 is absent.

DLH In both nasal cavities, moderate destruction of the conchal & turbinate structures is seen. The frontal sinuses are not appreciated and replaced by trabecular bone

SEX The tympanic bullae bilaterally are occupied by fluid attenuating material, the osseous lining is mild to moderately thickened and mildly irregular, R>L. The external ear canals are within normal limits.

MN

AGE Both temporomandibular joints present congruent joint spaces with even subchondral bone surfaces and are considered within normal limits.

9 Years

The brain presents no deviation from normal anatomy and symmetry. The brain parenchyma is homogeneous and within normal limits for attenuation and distribution of contrast enhancement. The ventricular system is non-dilated and symmetric.

INTERPRETED BY

Sebastian Schaub, DVM
Dr. med. vet. DipECVDI

The submandibular and medial retropharyngeal lymph nodes are small and elongated with a normal short-to-long-axis-ratio is < 0.5, the attenuation and contrast enhancement pattern is uniform.

HOSPITAL NAME

The left thyroid gland is significantly enlarged, measuring up to 10 mm in diameter, presenting a heterogeneous contrast enhancement pattern.

Bluegrass Veterinary
Specialists

COMPUTED TOMOGRAPHIC DIAGNOSIS

REFERRING VET

Gover

- Bilateral otitis media
- Destructive rhinitis
- Nodular enlargement left thyroid gland
- Absent triadan 407

INTERPRETATION OF THE FINDINGS & FURTHER RECOMMENDATIONS

INVOICE

52580

The otitis media can be a source for the Horner's syndrome. Either conservative or surgical management of the otitis media can be considered. The otitis media can be a sequela to rhinitis. The most likely underlying cause for the destructive rhinitis is primary viral ± bacterial superinfection.

DATE

6-23-22

The enlarged left thyroid gland is suggestive for (non)functional thyroid adenoma, correlate with findings from blood work.



PATIENT

Lance Edwards

SPECIES

Feline

BREED

DLH

SEX

MN

AGE

9 Years

INTERPRETED BY

Sebastian Schaub, DVM
Dr. med. vet. DipECVDI

HOSPITAL NAME

Bluegrass Veterinary
Specialists

REFERRING VET

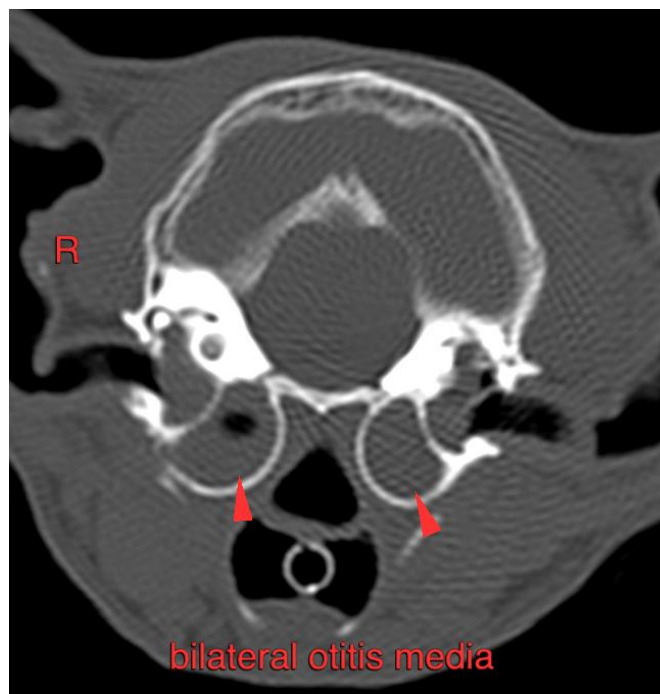
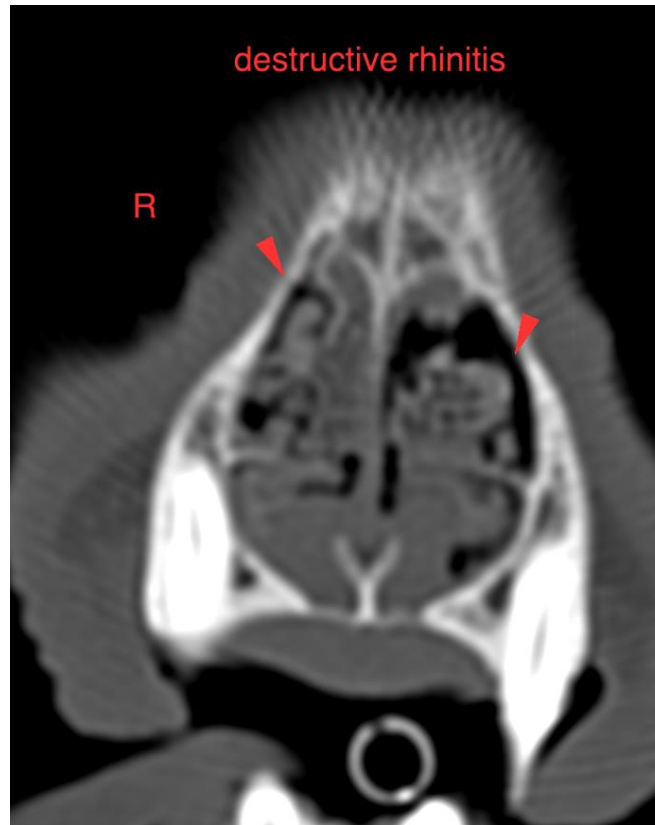Gover

INVOICE

52580

DATE

6-23-22





PATIENT

Lance Edwards

SPECIES

Feline

BREED

DLH

SEX

MN

AGE

9 Years

INTERPRETED BY

Sebastian Schaub, DVM
Dr. med. vet. DipECVDI

HOSPITAL NAME

Bluegrass Veterinary
Specialists

REFERRING VET

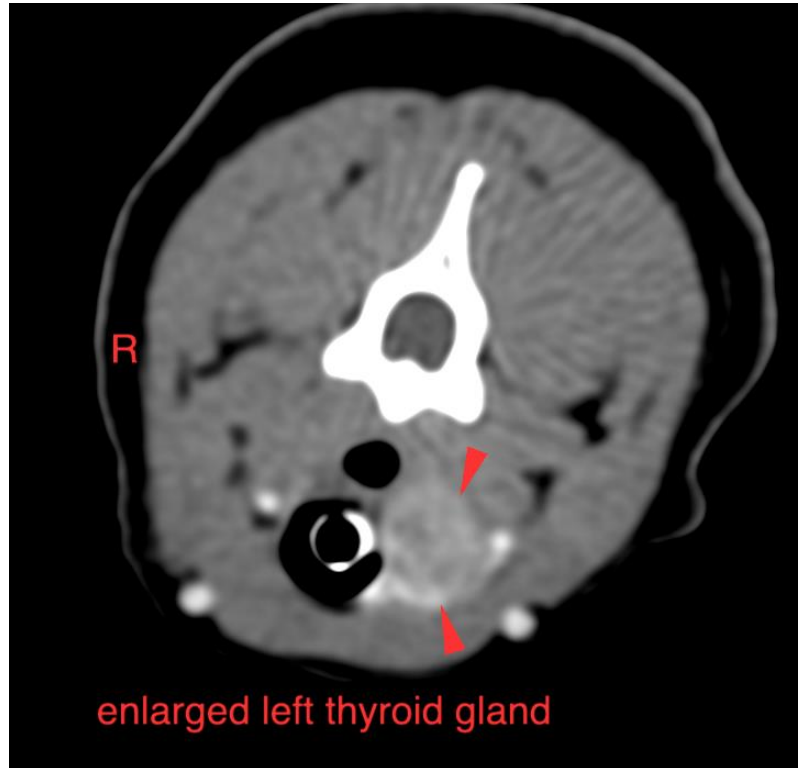
Gover

INVOICE

52580

DATE

6-23-22



The information and recommendations provided are based on the images presented by the referring veterinarian/sonographer. No evaluation can be communicated regarding pathology that was not visible in the image/video clips provided.

Thank you for this referral. If the clinical or image interpretation does not parallel your findings or if I can be of any further assistance please contact me.

Sebastian Schaub, Sebastian Schaub, DVM, Dr. med. vet. DipECVDI
sebast.schaub@gmail.com