



PATIENT PRESENTING CLINICAL SIGNS

Sammy Knuckman Diarrhea, ascites, giardia, alb of 1.8 last week, now 2.2 and stools have improved since metro and diet change. All else normal. Chest fine. App good, no vomiting

SPECIES RADIOGRAPHIC STUDY OF THE ABDOMEN

Ca Radiographs of the abdomen in two orthogonal planes are provided for review.

RADIOGRAPHIC FINDINGS

BREED The surrounding bony structures are within normal limits.

Husky No abnormalities of the extraabdominal soft tissues are noted. The abdominal wall is smooth and thin.
The serosal detail is age related decreased.

SEX The liver is appropriate in position, size and presents uniform opacity.

n/a The spleen, kidneys and bladder cannot be clearly delineated.

The stomach is in its anticipated position and moderately distended by gas and contains a small amount of kibbles.

AGE The small intestinal loops are generalized distended by gas as well as the colon.

15 Weeks

RADIOGRAPHIC DIAGNOSIS

INTERPRETED BY

- Generalized gas distended gastrointestinal tract

Sebastian Schaub, DVM
Dr. med. vet. DipECVDI

INTERPRETATION OF THE FINDINGS & FURTHER RECOMMENDATIONS

The generalized gas pattern of the gastrointestinal tract in combination with the described clinical signs is suggestive for underlying gastroenteritis – possibly due to dysbacteriosis, dietary indiscretion or parasitic infection. The gas pattern can be accentuated by stress related aerophagia.

HOSPITAL NAME

Bayshore Veterinary
Hospital

REFERRING VET

Stretton

INVOICE

58987

DATE

6-22-23



PATIENT

Sammy Knuckman

SPECIES

Ca

BREED

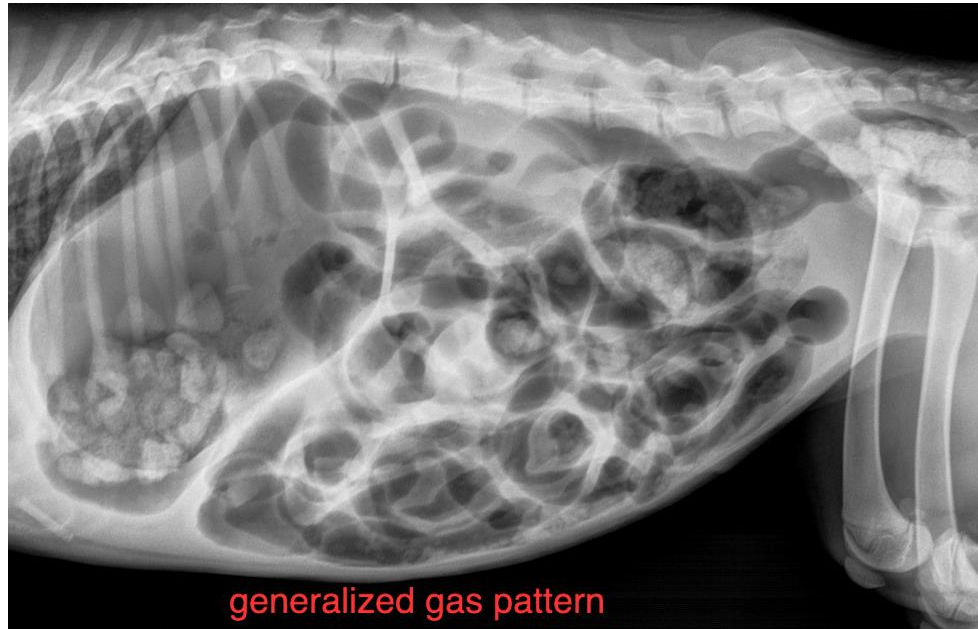
Husky

SEX

n/a

AGE

15 Weeks



INTERPRETED BY

Sebastian Schaub, DVM
Dr. med. vet. DipECVDI

The information and recommendations provided are based on the images presented by the referring veterinarian/sonographer. No evaluation can be communicated regarding pathology that was not visible in the image/video clips provided.

Thank you for this referral. If the clinical or image interpretation does not parallel your findings or if I can be of any further assistance please contact me.

HOSPITAL NAME

Bayshore Veterinary
Hospital

Sebastian Schaub, Sebastian Schaub, DVM, Dr. med. vet. DipECVDI
info@sonopath.com

REFERRING VET

Stretton

INVOICE

58987

DATE

6-22-23