



PATIENT

Marshall Atherton

PRESENTING CLINICAL SIGNS

1 year history of on off ear issues. Pseudomonas cultured previously (no significant pattern of resistance at this time- 04/22) and was on marbocyl tablets, then aurizon. Recent culture resistant to enrofloxacin and intermediate sensitivity to marbofloxacin. Has been on marbofloxacin so consider alternative a/b with good sensitivity. Ideally CT to check extent of infection

SPECIES

Canine

COMPUTED TOMOGRAPHY OF THE SKULL

A high resolution pre- and post-contrast CT study of the skull is provided for review.

BREED

Labrador

COMPUTED TOMOGRAPHIC FINDINGS

Triadan 308 & 408 are absent.

SEX

Male

The nasal cavity presents the expected aerated spaces between thin & even conchae and turbinates with smooth mucosal lining.

Both temporomandibular joints present congruent joint spaces with even subchondral bone surfaces and are considered within normal limits.

AGE

6 Years

Both tympanic bullae are aerated, the mucosal lining is not seen, the bony wall is smooth and thin. The wall of the external ear canals is mild to moderately thickened, L>R. The left external ear canal is mildly narrowed.

INTERPRETED BY

Sebastian Schaub, DVM
Dr. med. vet. DipECVDI

The brain presents no deviation from normal anatomy and symmetry. The brain parenchyma is homogeneous and within normal limits for attenuation and distribution of contrast enhancement. The ventricular system is non-dilated and symmetric.

The submandibular and medial retropharyngeal lymph nodes are small and elongated with a normal short-to-long-axis-ratio is < 0.5, the attenuation and contrast enhancement pattern is uniform.

HOSPITAL NAME

Animal Trust -
Ellesmere Port

COMPUTED TOMOGRAPHIC DIAGNOSIS

- History of bilateral otitis externa, L>R
- Absent triadan 308&408

REFERRING VET

Laura Hughes

INTERPRETATION OF THE FINDINGS & FURTHER RECOMMENDATIONS

The findings the external ear canals is fitting the history or otitis externa with swelling of the external ear canals. There is no evidence of accompanying otitis media.

INVOICE

52569

DATE

6-22-22



PATIENT

Marshall Atherton

SPECIES

Canine

BREED

Labrador

SEX

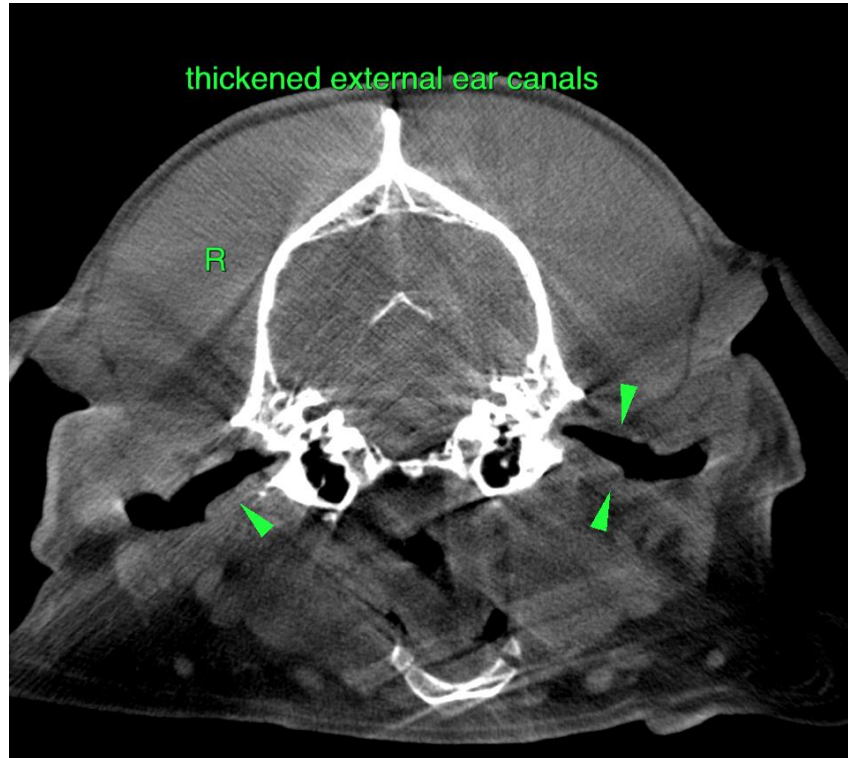
Male

AGE

6 Years

INTERPRETED BY

Sebastian Schaub, DVM
Dr. med. vet. DipECVDI



thickened external ear canals

HOSPITAL NAME

Animal Trust -
Ellesmere Port

REFERRING VET

Laura Hughes

The information and recommendations provided are based on the images presented by the referring veterinarian/sonographer. No evaluation can be communicated regarding pathology that was not visible in the image/video clips provided.

Thank you for this referral. If the clinical or image interpretation does not parallel your findings or if I can be of any further assistance please contact me.

Sebastian Schaub, Sebastian Schaub, DVM, Dr. med. vet. DipECVDI
sebast.schaub@gmail.com

INVOICE

52569

DATE

6-22-22