

**PATIENT PRESENTING CLINICAL SIGNS**

Koko Hernandez Limping intermittently left front limb for about 2 weeks. The same thing happened back in 4/7, he was treated with Meloxicam and Dasuquin and he got better.
Abnormal PE/Chem/CBC/UA Results: CBC: Lym 6200 H, otherwise WNL Chemistry WNL

SPECIES COMPUTED TOMOGRAPHY OF THE FRONT LIMBS

Canine A high resolution pre- and post-contrast CT study of shoulder & elbow joints are provided for review.

COMPUTED TOMOGRAPHIC FINDINGS**BREED**

Goldendoodle

The subchondral bone at the caudal aspect of the left humeral head presents an irregular marginated, crescent shaped defect, measuring 1.4 x 1.2 x 0.1 mm. The defect is demarcated by zone of mild sclerosis of the subchondral bone. A thin c-shaped mineral attenuating lamella is seen in the caudodistal outpouching of the joint capsule of the left shoulder joint. There is evidence of moderate intracapsular soft tissue swelling.

SEX

Male

The right shoulder joint presents smooth osseous margins of the periarticular bones and without abnormalities of the surrounding soft tissue structures.

AGE

7 Months

Both elbow joints present smooth osseous margins; the medial coronoid process of the elbow joints is well-defined and has a homogeneous density, unremarkable. The soft tissue structures surrounding the elbow joints present no abnormalities.

COMPUTED TOMOGRAPHIC DIAGNOSIS**INTERPRETED BY**

Sebastian Schaub, DVM
Dr. med. vet. DipECVDI

- Osteochondrosis dissecans (OCD) left humeral head
- Secondary joint effusion left shoulder joint
- Normal right shoulder joint
- Normal elbow joints bilaterally

HOSPITAL NAME

Mobile Pet Imaging

INTERPRETATION OF THE FINDINGS & FURTHER RECOMMENDATIONS

The OCD lesion of the left shoulder joint is a plausible explanation for the left front limb lameness. Surgical management by the means of arthroscopy or arthrotomy is considered beneficial.

REFERRING VET

Villasmil

INVOICE

58958

DATE

6-21-23



PATIENT

Koko Hernandez

SPECIES

Canine

BREED

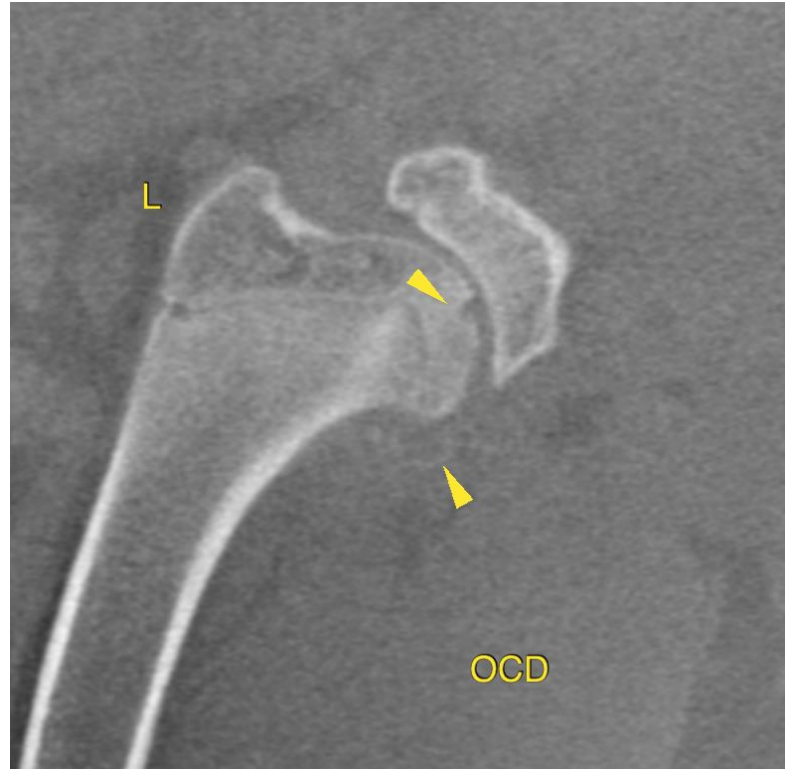
Goldendoodle

SEX

Male

AGE

7 Months



INTERPRETED BY

Sebastian Schaub, DVM
Dr. med. vet. DipECVDI

HOSPITAL NAME

Mobile Pet Imaging

REFERRING VET

Villasmil

INVOICE

58958

DATE

6-21-23

The information and recommendations provided are based on the images presented by the referring veterinarian/sonographer. No evaluation can be communicated regarding pathology that was not visible in the image/video clips provided.

Thank you for this referral. If the clinical or image interpretation does not parallel your findings or if I can be of any further assistance please contact me.

Sebastian Schaub, Sebastian Schaub, DVM, Dr. med. vet. DipECVDI
info@sonopath.com