



PATIENT PRESENTING CLINICAL SIGNS

Taina Correa Patient presents with severe atrophy of the muscles on the right side of the head. He has no ear infection. Rimadyl x 7d and Gabapentin 100mg SID x 7d were started. After 1 week in a follow-up appointment, Taina presents head to one side and little coordination when walking. Gabapentin bid was increased, rimadyl was discontinued, and Prednisone was started on Thursday, June 15, 2022

SPECIES

Canine Abnormal PE/Chem/CBC/UA Results: CBC --- unremarkable CHEM --- unremarkable

COMPUTED TOMOGRAPHY OF THE SKULL

BREED

A high resolution pre- and post-contrast CT study of the skull is provided for review.

Schnauzer

COMPUTED TOMOGRAPHIC FINDINGS

Triadan 107 presents a significant widening of the periodontal space and resorptive lesions of the roots. Triadan 210 presents a moderate widening of the periodontal space.

SEX

F

The volume of the right temporalis muscle, right masseter muscle, right pterygoid muscle and rostral part of the right digastric muscle is markedly decreased. The right tympanic bulla is filled with fluid attenuating material, the osseous lining is smooth and thin.

AGE

8 Years

The diameter of the right trigeminal nerve, level with the osseous trigeminal canal is mild to moderately increased with increased contrast enhancement in comparison to the contralateral side. Level with the origin of the right trigeminal nerve from the lateral aspect of the pons, a mild irregular roundish, moderate contrast enhancing mass is appreciated, measuring 9 mm in diameter; an associated dural tail sign is noted. No increased diameter of the branches of the right trigeminal nerve is appreciated.

INTERPRETED BY

Sebastian Schaub, DVM
Dr. med. vet. DipECVDI

The nasal cavity presents the expected aerated spaces between thin & even conchae and turbinates with smooth mucosal lining.

HOSPITAL NAME

Veterinary Image Center

Both temporomandibular joints present congruent joint spaces with even subchondral bone surfaces and are considered within normal limits.

Both tympanic bullae are aerated, the mucosal lining is not seen, the bony wall is smooth and thin. The external ear canals are within normal limits.

REFERRING VET

Dr. D. Trautmann

The submandibular and medial retropharyngeal lymph nodes are small and elongated with a normal short-to-long-axis-ratio is < 0.5, the attenuation and contrast enhancement pattern is uniform.

COMPUTED TOMOGRAPHIC DIAGNOSIS

INVOICE

52547

- Intracranial extraaxial mass level with origin of the right trigeminal nerve and segmental neuropathy of the trigeminal nerve
- Neurogenic muscle atrophy right masticatory muscles
- Secondary right sided otitis media due to altered function of the levator palatini muscle
- Advanced periodontal disease 107 and 210

DATE

6-21-22

INTERPRETATION OF THE FINDINGS & FURTHER RECOMMENDATIONS

The findings are consistent with extraaxial neoplastic disease level with the trigeminal nerve, due to the dural tail sign, I consider the odds for mass originating from the meningeal lining higher (e.g. round cell tumor, meningioma) than for peripheral malignant nerve sheath tumor. The



PATIENT

Taina Correa

finding is a plausible explanation for the clinical signs. If not done so yet, complementing workup by a CSF tap is recommended. If it is therapeutical relevant, the CT study might be complemented by MR study of the skull.

SPECIES

Canine

BREED

Schnauzer

SEX

F

AGE

8 Years

INTERPRETED BY

Sebastian Schaub, DVM
Dr. med. vet. DipECVDI

HOSPITAL NAME

Veterinary Image
Center

REFERRING VET

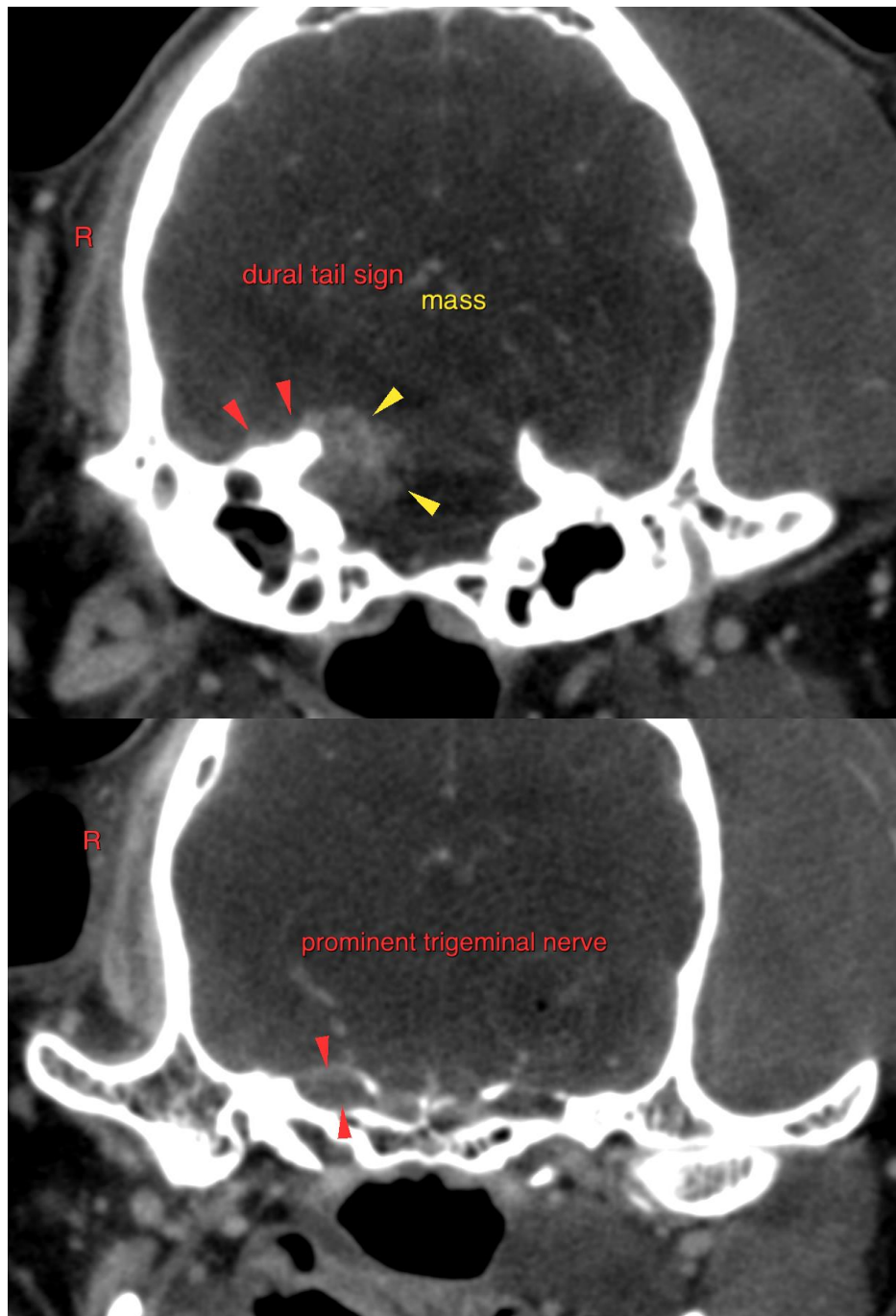
Dr. D. Trautmann

INVOICE

52547

DATE

6-21-22





PATIENT

Taina Correa

The information and recommendations provided are based on the images presented by the referring veterinarian/sonographer. No evaluation can be communicated regarding pathology that was not visible in the image/video clips provided.

Thank you for this referral. If the clinical or image interpretation does not parallel your findings or if I can be of any further assistance please contact me.

SPECIES

Canine

Sebastian Schaub, Sebastian Schaub, DVM, Dr. med. vet. DipECVDI
sebast.schaub@gmail.com

BREED

Schnauzer

SEX

F

AGE

8 Years

INTERPRETED BY

Sebastian Schaub, DVM
Dr. med. vet. DipECVDI

HOSPITAL NAME

Veterinary Image
Center

REFERRING VET

Dr. D. Trautmann

INVOICE

52547

DATE

6-21-22