



PATIENT

Maverick Spencer

PRESENTING CLINICAL SIGNS

History of epistaxis Feb 20/22, diagnosed elsewhere with hypertension. Poorly responsive to hypertension meds. VIN consul suspected not hypertension. Stopped meds, epistaxis again. Started meds again for 1 week. Stopped meds for 2 days, no epistaxis, blood pressure systolic 175 mmHG. Also history of choke like episodes for 1 month. Suspect mass (nasal or nasopharyngeal)
 Abnormal PE/Chem/CBC/UA Results: Increased WBC 18.24 x 19^9/L

SPECIES

Canine

COMPUTED TOMOGRAPHY OF THE SKULL

A high resolution pre- and post-contrast CT study of the skull is provided for review.

BREED

Border Collie X

COMPUTED TOMOGRAPHIC FINDINGS

The pictured parts of the dentition are complete and unremarkable in all jaw quadrants.

SEX

MN

The left nasal cavity and the left frontal sinus are partially occupied by a uniform soft tissue attenuating and heterogeneous contrast enhancing mass - centered on the left maxillary bone and left frontal bone. The associated osseous structures present advanced aggressive osteolytic lesions and the mass is bulging into the left frontal sinus. Lysis of the cribriform plate with perforation of the cranial fossa is noted.

AGE

10 Years, 9 Months

Both temporomandibular joints present congruent joint spaces with even subchondral bone surfaces and are considered within normal limits.

INTERPRETED BY

Sebastian Schaub, DVM
 Dr. med. vet. DipECVDI

Both tympanic bullae are aerated, the mucosal lining is not seen, the bony wall is smooth and thin. The external ear canals are within normal limits.

The brain presents no deviation from normal anatomy and symmetry. The brain parenchyma is homogeneous and within normal limits for attenuation and distribution of contrast enhancement. The ventricular system is non-dilated and symmetric.

HOSPITAL NAME

Bridgwater
 Veterinary Hospital
 and Wellness Centre

The left submandibular and medial retropharyngeal lymph node are mildly prominent

COMPUTED TOMOGRAPHIC DIAGNOSIS

- Left sided biologically aggressive nasal soft tissue neoplasia with polyostotic aggressive osteolytic lesions and perforation of the cranial fossa
- Mild lymphadenopathy left mandibular lymph nodes and left medial retropharyngeal lymph node

REFERRING VET

Dr. D. Williams

INTERPRETATION OF THE FINDINGS & FURTHER RECOMMENDATIONS

There is a biologically aggressive nasal soft tissue mass causing extensive osteolysis of the associated osseous structures with signs for perforation of the cranial fossa. Differentials include adenocarcinoma, squamous cell carcinoma, transitional cell carcinoma, lymphosarcoma, other. Rhinoscopy including biopsy or FNA sampling of the swelling rostral to the right orbit can be used as advanced diagnostic tests. Based on the results of the advanced diagnostic tests, the chances of radiation therapy can be discussed with oncologist. The Adam tumor stage is T4.

INVOICE

52556

DATE

6-21-22

The prominent tributary lymph nodes are equivocal for reactive hyperplasia versus metastatic spread. Consider full tumor staging including FNA sampling of the regional lymph nodes.



PATIENT

Maverick Spencer

SPECIES

Canine

BREED

Border Collie X

SEX

MN

AGE

10 Years, 9 Months

INTERPRETED BY

Sebastian Schaub, DVM
Dr. med. vet. DipECVDI

HOSPITAL NAME

Bridgwater
Veterinary Hospital
and Wellness Centre

REFERRING VET

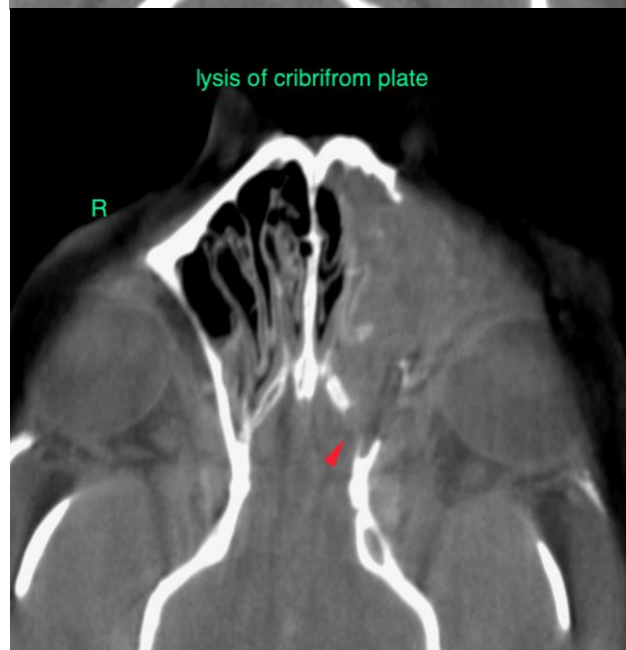
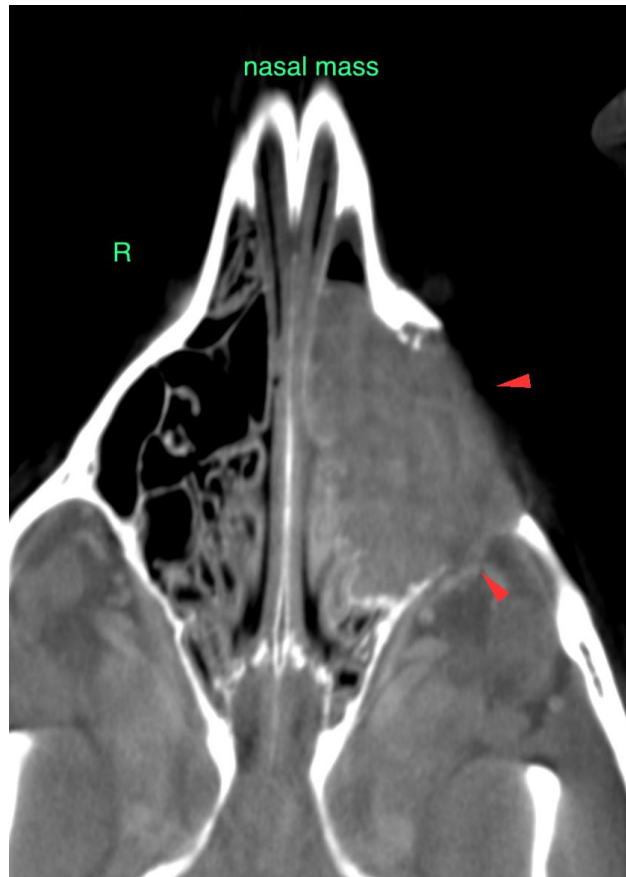Dr. D. Williams

INVOICE

52556

DATE

6-21-22





PATIENT

Maverick Spencer

SPECIES

Canine

BREED

Border Collie X

SEX

MN

AGE

10 Years, 9 Months

INTERPRETED BY

Sebastian Schaub, DVM
Dr. med. vet. DipECVDI

HOSPITAL NAME

Bridgwater
Veterinary Hospital
and Wellness Centre

REFERRING VET

Dr. D. Williams

INVOICE

52556

DATE

6-21-22

The information and recommendations provided are based on the images presented by the referring veterinarian/sonographer. No evaluation can be communicated regarding pathology that was not visible in the image/video clips provided.

Thank you for this referral. If the clinical or image interpretation does not parallel your findings or if I can be of any further assistance please contact me.

Sebastian Schaub, Sebastian Schaub, DVM, Dr. med. vet. DipECVDI
sebast.schaub@gmail.com