



PATIENT PRESENTING CLINICAL SIGNS

Toby Schmit Mild-moderate weight bearing left forelimb lameness started about 3 weeks ago after Toby was hit in the side with door opening. Some mild reactivity to palpation of biceps tendon. Otherwise no pain on orthopedic exam. Minimal improvement on carprofen.

SPECIES RADIOGRAPHIC STUDY OF THE SHOULDER AND ELBOW JOINTS

Canine A complete set of radiographs of the shoulder and elbow joints is provided for review.

RADIOGRAPHIC FINDINGS

BREED
Golden Retriever Mix Both shoulder joints present smooth osseous margins and the surrounding soft tissue structures are within normal limits.

The periarticular bones of the left elbow joint present mild osteophyte new bone formation. The contour of the medial coronoid process is ill-defined and the tip cannot be clearly defined.

SEX
MN The osseous margins of the right elbow joint are smooth; the contour of the medial coronoid process is well-defined and has a homogeneous density.

RADIOGRAPHIC DIAGNOSIS

- AGE**
6 Years, 7 Months
- Coronoid disease left elbow joint
 - Degenerative osteoarthritis left elbow joint
 - Normal right elbow joint
 - Normal shoulder joints

INTERPRETED BY

Sebastian Schaub, DVM
Dr. med. vet. DipECVDI

INTERPRETATION OF THE FINDINGS & FURTHER RECOMMENDATIONS

The radiographic changes are consistent with coronoid disease of the left elbow joint and secondary degenerative osteoarthritis. The changes of the left elbow joint can be a source for the left front limb lameness. A CT study of the elbow joints can be used as advanced imaging modality.

HOSPITAL NAME

Gentle Doctor Animal
Hospital

No abnormalities of the shoulder joints are appreciated, explaining the front limb lameness. In case of strong suspicion for underlying pathology of the bicipital tendon, consider an ultrasound examination of the left shoulder joint.

REFERRING VET

Dr. Rotthaus

INVOICE

58943

DATE

6-20-23



PATIENT

Toby Schmit

SPECIES

Canine

BREED

Golden Retriever Mix

SEX

MN

AGE

6 Years, 7 Months

INTERPRETED BY

Sebastian Schaub, DVM
Dr. med. vet. DipECVDI

HOSPITAL NAME

Gentle Doctor Animal
Hospital

REFERRING VET

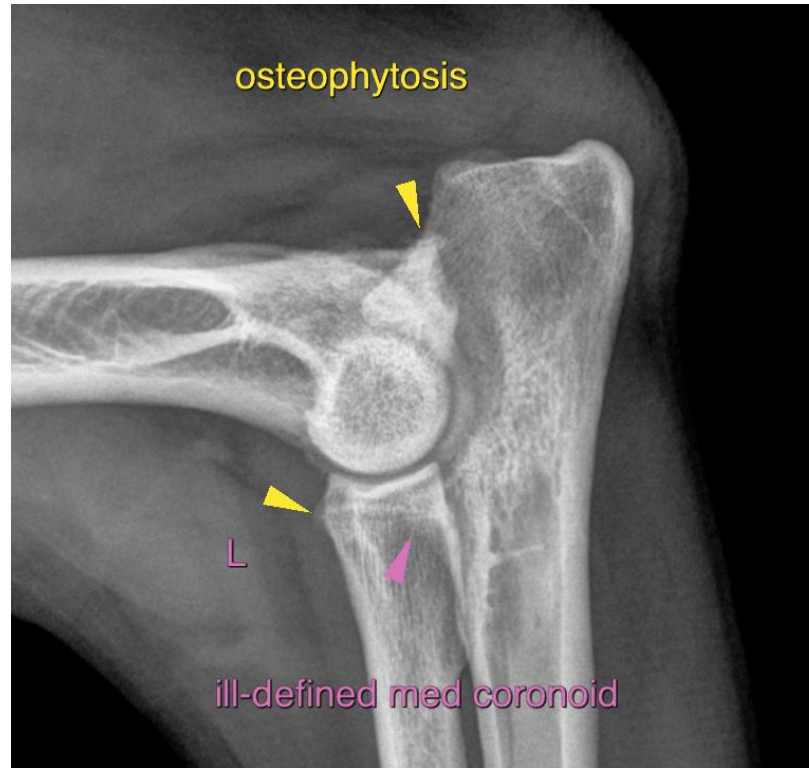
Dr. Rotthaus

INVOICE

58943

DATE

6-20-23



The information and recommendations provided are based on the images presented by the referring veterinarian/sonographer. No evaluation can be communicated regarding pathology that was not visible in the image/video clips provided.

Thank you for this referral. If the clinical or image interpretation does not parallel your findings or if I can be of any further assistance please contact me.

Sebastian Schaub, Sebastian Schaub, DVM, Dr. med. vet. DipECVDI
info@sonopath.com