



PATIENT PRESENTING CLINICAL SIGNS

Copper Schnaitman Owner came home from vacation, Copper became very excited, then collapsed/fainted. Seems to take a couple minutes to start wagging his tail and ambulate but tongue was pale for longer than owner thought was ok. Has been otherwise ok since last visit and while owners were on vacation.

SPECIES Abnormal PE/Chem/CBC/UA Results: mm- pale pink, tongue pale pink. Soft, non painful abdomen, no masses/organomegaly appreciated. Dull/muffled heart- no murmur heard but bradycardia present. Lungs/Trachea- WNL and panting. Lymph nodes- can feel both popliteal but not enlarged. Musculoskeletal- stable previous neck issue. Blood work, ECG WNL, FAST Scan of abdomen shows no obvious abnormalities.

BREED RADIOGRAPHIC STUDY OF THE ABDOMEN AND CERVICAL SPINE

Golden Retriever Mix Radiographs of the cervical spine and the abdomen in a laterolaterale view are provided for review.

RADIOGRAPHIC FINDINGS

SEX Cervical spine

Male Neuter The lateral projection of the cervical spine is moderately rotated.

AGE

The vertebral endplates C4/C5 present moderate spondylosis formation and the respective intervertebral disc space appears narrowed.

12 Years, 3 Months

The remainder of the osseous and soft tissue structures of the cervical spine and neck are within normal limits.

INTERPRETED BY

Abdomen

Sebastian Schaub, DVM
Dr. med. vet. DipECVDI

The vertebral endplates T13/L1 and L5/L6 present moderate spondylosis formation.

No abnormalities of the extraabdominal soft tissues are noted. The abdominal wall is smooth and thin.

HOSPITAL NAME

The serosal detail is maintained throughout the peritoneal and retroperitoneal space.

POCONO PEAK
VETERINARY
CENTER

The liver is appropriate in position, size and presents uniform opacity.

The splenic body and tail are considered normal for position, size, shape and opacity.

REFERRING VET

Both kidneys are seen and present with normal size, shape, delineation and opacity. The urinary bladder is in its anticipated position. No radiopaque calculi are noted throughout the upper and lower urinary tract.

Nicole Norris-Carney

The stomach is in its anticipated position and presents normal content.

The small intestinal loops are of even diameter and non-dilated, a small amount of gas is seen within the small intestinal loops and considered within normal limits.

INVOICE

The colon is seen in the expected position and presents with appropriate content.

58916

RADIOGRAPHIC DIAGNOSIS

DATE

- Suspect discopathy C4/C5
- Spondylosis deformans C4/C5, T13/L1 and L5/L6

6-20-23



PATIENT INTERPRETATION OF THE FINDINGS & FURTHER RECOMMENDATIONS

Copper Schnaitman

The degenerative changes level C4/C5 are suggestive for underlying discopathy – although the supposed narrowing can be due to oblique projection of the respective intervertebral disc space. – that might or might not be associated with compressive myelopathy.

SPECIES

The abdomen presents without abnormalities.

Canine

BREED

Golden Retriever Mix

SEX

Male Neuter

AGE

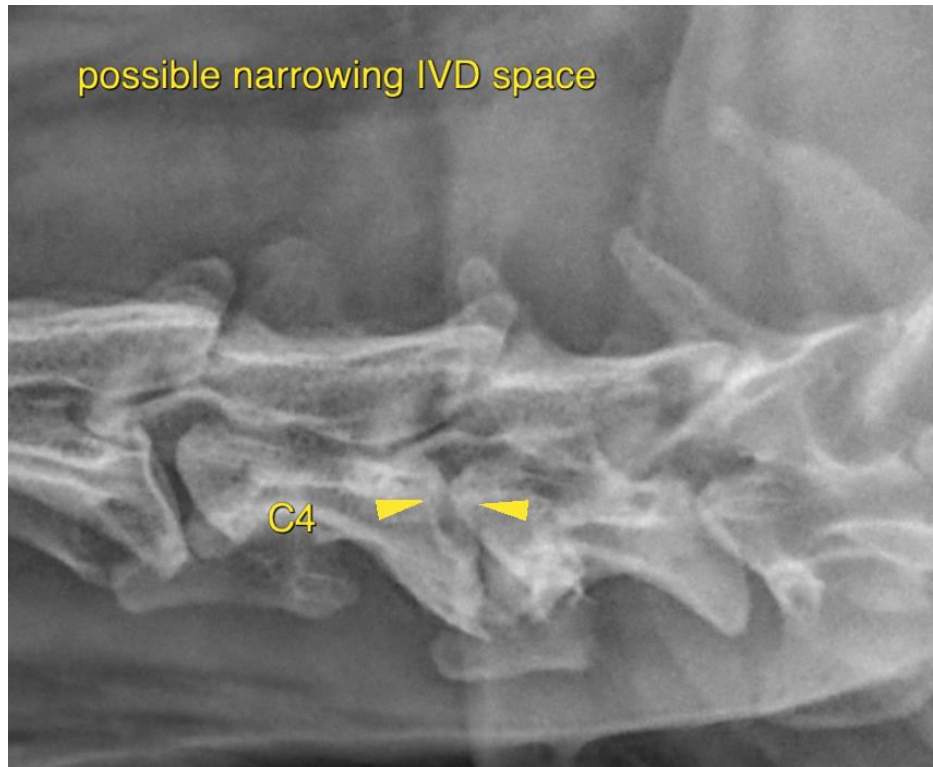
12 Years, 3 Months

INTERPRETED BY

Sebastian Schaub, DVM
Dr. med. vet. DipECVDI

HOSPITAL NAME

POCONO PEAK
VETERINARY
CENTER



REFERRING VET

Nicole Norris-Carney

The information and recommendations provided are based on the images presented by the referring veterinarian/sonographer. No evaluation can be communicated regarding pathology that was not visible in the image/video clips provided.

INVOICE

58916

Thank you for this referral. If the clinical or image interpretation does not parallel your findings or if I can be of any further assistance please contact me.

Sebastian Schaub, Sebastian Schaub, DVM, Dr. med. vet. DipECVDI
info@sonopath.com

DATE

6-20-23