

**PATIENT PRESENTING CLINICAL SIGNS**

Bailey Dukes Limping affecting front limbs; previous hind limb lameness- pet had TPLO.

COMPUTED TOMOGRAPHY OF THE FRONT LIMBS AND PELVIS

SPECIES A high resolution pre- and post-contrast CT study of the front limbs and the elbow joints are provided for review.

Canine

COMPUTED TOMOGRAPHIC FINDINGS

The osseous and surrounding soft tissue structures of both front limbs are within normal limits.

BREED

Bulldog

The right elbow joint presents smooth osseous margins, the medial coronoid process is well-defined, unremarkable.

SEX

The left elbow joint presents with mild to moderate motion artefacts, causing double contour of the osseous margins. The medial coronoid process of the left elbow joint presents a mild heterogeneous attenuation pattern with a reduced density of the tip of the medial coronoid process.

Neutered Male

The surrounding soft tissue structures are within normal limits. Both coxofemoral joints present mild osteophyte formation.

AGE

1 Year

COMPUTED TOMOGRAPHIC DIAGNOSIS

- Possible coronoid pathology left elbow joint
- Mild degenerative osteoarthritis coxofemoral joints bilaterally, suspect mild hip dysplasia
- Structural normal shoulder joints bilaterally
- Structural normal right elbow joint

INTERPRETED BY

Sebastian Schaub, DVM
Dr. med. vet. DipECVDI

INTERPRETATION OF THE FINDINGS & FURTHER RECOMMENDATIONS**HOSPITAL NAME**

Mobile Pet Imaging

Unfortunately, the left elbow joint presents with motion artefacts limiting the diagnostic value. The medial coronoid process of the left elbow joint appears to present a heterogeneous density, concerning for coronoid disease, however the heterogeneity can be a sequela to the motion artefacts as well. In case of doubt, recommend repeating the CT scan of the left elbow joint.

REFERRING VET

Meaux

INVOICE

52524

DATE

6-20-22



PATIENT

Bailey Dukes

SPECIES

Canine

BREED

Bulldog

SEX

Neutered Male

AGE

1 Year

INTERPRETED BY

Sebastian Schaub, DVM
Dr. med. vet. DipECVDI

HOSPITAL NAME

Mobile Pet Imaging

REFERRING VET

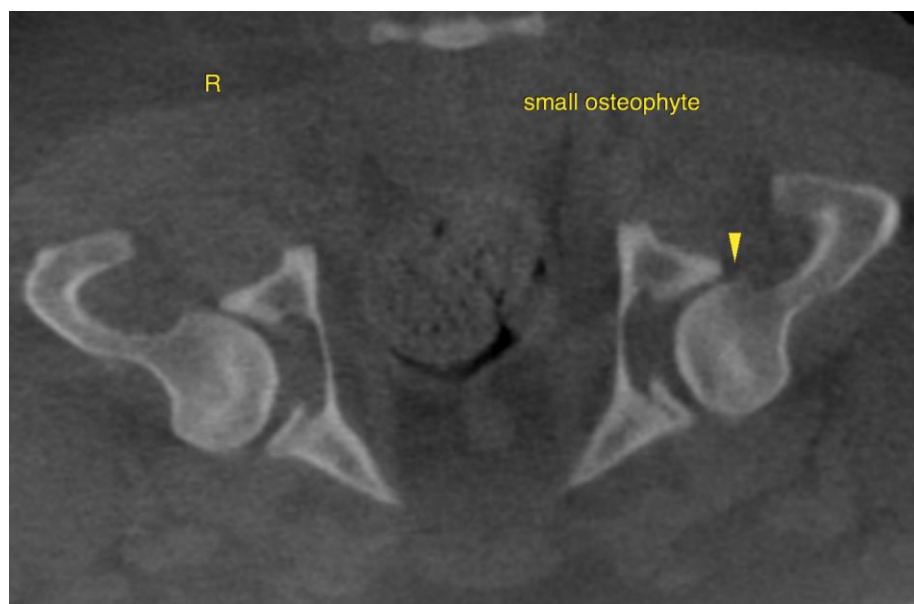
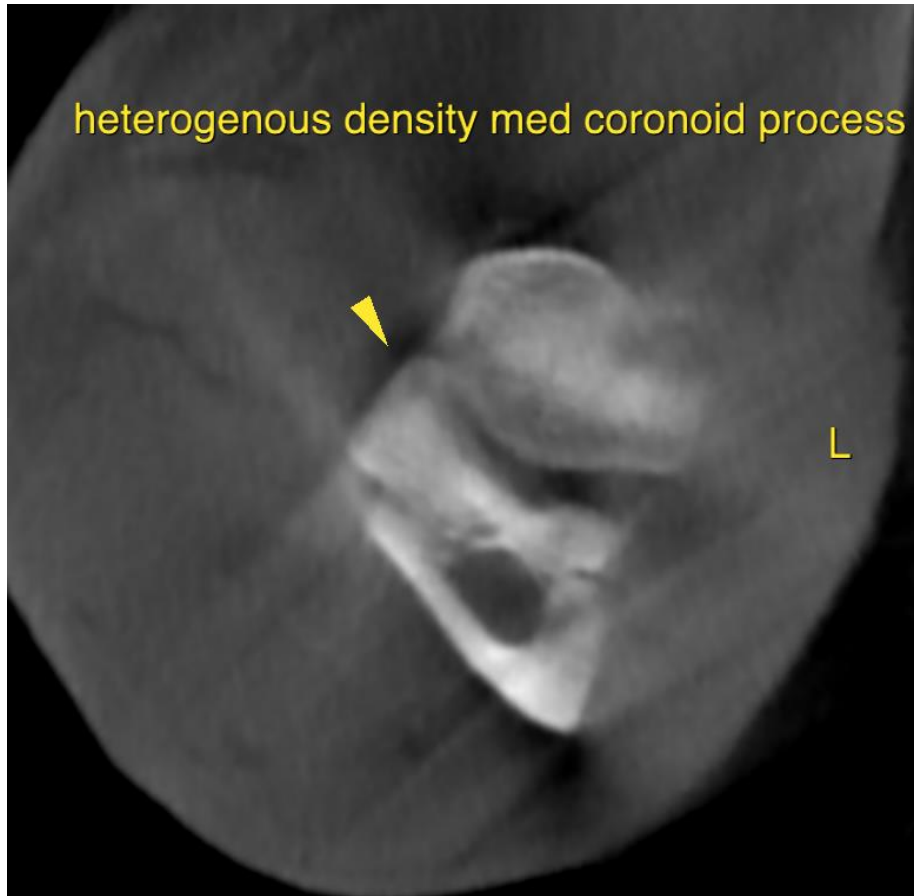
Meaux

INVOICE

52524

DATE

6-20-22





PATIENT

Bailey Dukes

SPECIES

Canine

The information and recommendations provided are based on the images presented by the referring veterinarian/sonographer. No evaluation can be communicated regarding pathology that was not visible in the image/video clips provided.

BREED

Bulldog

Thank you for this referral. If the clinical or image interpretation does not parallel your findings or if I can be of any further assistance please contact me.

SEX

Neutered Male

Sebastian Schaub, Sebastian Schaub, DVM, Dr. med. vet. DipECVDI
sebast.schaub@gmail.com

AGE

1 Year

INTERPRETED BY

Sebastian Schaub, DVM
Dr. med. vet. DipECVDI

HOSPITAL NAME

Mobile Pet Imaging

REFERRING VET

Meaux

INVOICE

52524

DATE

6-20-22