

**PATIENT**

Aaron Desgorselliers

PRESENTING CLINICAL SIGNS

limping on back left leg & lethargic for 5 days. Owner thinks the cat fell from a chair during the last week

Abnormal PE/Chem/CBC/UA Results: PE- LIMPING ON HIND LEFT LEG, UNCOMFORTABLE UPON MANIPULATION OF THE LEFT STIFLE & HIP JOINT no tibial thrust or cranial drawer motion of tibia (for left stifile) BW- lymphocytosis, mild neutropenia, rest is WNL

SPECIES

Feline

RADIOGRAPHIC STUDY OF THE STIFLE JOINTS

Radiographs of the stifile joints in two imaging planes are provided for review.

BREED

Sphynx

RADIOGRAPHIC FINDINGS

The acetabular groove bilaterally is shallow and craniodorsal subluxation of the femoral heads is appreciated.

SEX

Male

The patella of the right stifile joint is superimposed on the medial femoral condyle. Both stifile joints present smooth osseous margins and without evidence of intracapsular soft tissue swelling.

AGE

1 Year

- Marked hip dysplasia bilaterally with secondary subluxation of the femoral heads
- Right sided medial patellar luxation

RADIOGRAPHIC DIAGNOSIS**INTERPRETED BY**

Sebastian Schaub, DVM
Dr. med. vet. DipECVDI

INTERPRETATION OF THE FINDINGS & FURTHER RECOMMENDATIONS

The main finding is the bilateral hip dysplasia with secondary subluxation of the femoral heads. Acute on chronic insult may have caused the acute onset of lameness. The clinical relevance of the right sided medial patellar luxation is unclear as the patient is lame in the left hind limb.

A clinical trial with NSAID and rest appears as the therapy of choice and reevaluating the patient if clinical signs are refractory to therapy.

HOSPITAL NAME

St. Catherine's Animal
Hospital

REFERRING VET

Dr. Jui Gokhale

INVOICE

52528

DATE

6-20-22



PATIENT

Aaron Desgorselliers

SPECIES

Feline

BREED

Sphynx

SEX

Male

AGE

1 Year

INTERPRETED BY

Sebastian Schaub, DVM
Dr. med. vet. DipECVDI

HOSPITAL NAME

St. Catherine's Animal
Hospital

REFERRING VET

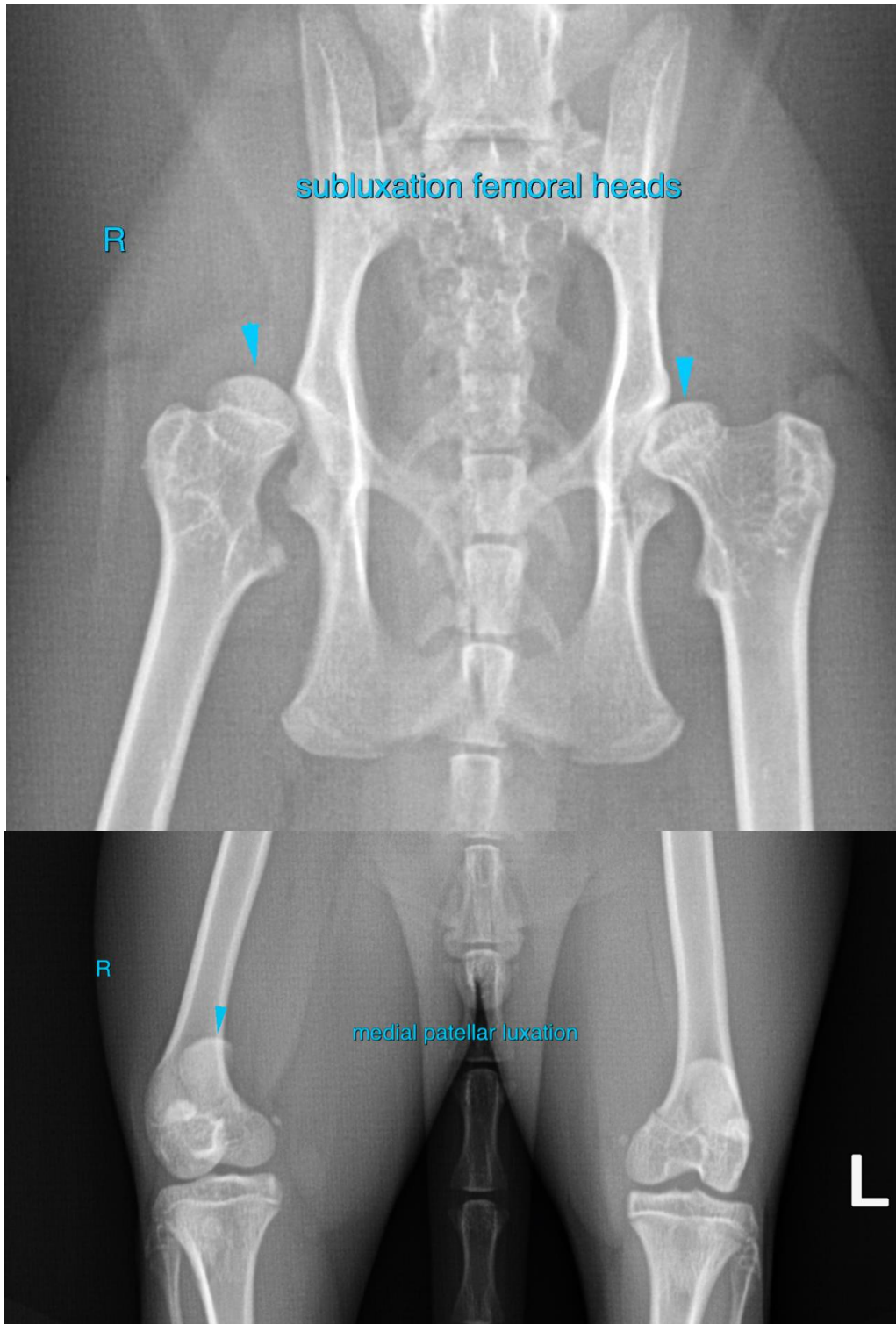
Dr. Jui Gokhale

INVOICE

52528

DATE

6-20-22





PATIENT

Aaron Desgorselliers

The information and recommendations provided are based on the images presented by the referring veterinarian/sonographer. No evaluation can be communicated regarding pathology that was not visible in the image/video clips provided.

SPECIES

Feline

Thank you for this referral. If the clinical or image interpretation does not parallel your findings or if I can be of any further assistance please contact me.

Sebastian Schaub, Sebastian Schaub, DVM, Dr. med. vet. DipECVDI
sebast.schaub@gmail.com

BREED

Sphynx

SEX

Male

AGE

1 Year

INTERPRETED BY

Sebastian Schaub, DVM
Dr. med. vet. DipECVDI

HOSPITAL NAME

St. Catherine's Animal
Hospital

REFERRING VET

Dr. Jui Gokhale

INVOICE

52528

DATE

6-20-22