



PATIENT

Rudy Dewicki

SPECIES

Rabbit

BREED

Mixed Breed

SEX

Male Castrated

AGE

8Y, 6M

WEIGHT

1.7kg

INTERPRETED BY

Sebastian Schaub, DVM
Dr. med. vet.
DipECVDI

IMAGING PERFORMED BY

Rachel Jacobs and
Ivana Levy

HOSPITAL NAME

Emergency Veterinary
Hospital of Ann Arbor

REFERRING VET

Ivana Levy

INVOICE

75259

DATE

6-2-26

PRESENTING CLINICAL SIGNS

at least 6m history of chronic nasal discharge and sneezing-minimal response to oral antibiotics. 3-4 week history of left sided ocular discharge and mild elevation of third eyelid with positive response to tobramycin ophthalmic. History of decreased mobility in hindlimb since adopted 3 month prior. Otherwise eating, drinking, acting normally besides single episode of GI stasis post veterinary visit 2 weeks prior that resolved with at home supportive care. Currently responding well to oral TMS and tobramycin ophthalmic with 7/10 quality of life at home

Abnormal PE/Chem/CBC/UA Results: PE: mild elevation of third eyelid OS with mild protrusion of eye. Minimal debris from nasolacrimal debris expressed OU, no evidence of nasal or ocular discharge OU in hospital, but a few sneezing noises heard in hospital. CBC: Mild inflammatory leukogram Chem: elevated globulin, consideration for chronic inflammation

COMPUTED TOMOGRAPHY OF THE SKULL

A high resolution pre- and post-contrast CT study of the skull is provided for review.

COMPUTED TOMOGRAPHIC FINDINGS

The pictured parts of the dentition are complete. Triadan 407 presents a loss of the normal hypoattenuating striation, is mildly retrograde elongated and is generalized increased in size. The crown of triadan 407 is mildly elongated. The remainder of the dentition reveal no abnormalities.

In the left nasal cavity, advanced destruction of the nasal conchal structures is appreciated. In the right nasal cavity, small zones with consolidation are appreciated.

Both temporomandibular joints present congruent joint spaces with even subchondral bone surfaces and are considered within normal limits.

Both tympanic bullae are aerated, the mucosal lining is not seen, the bony wall is smooth and thin. The external ear canals are within normal limits.

COMPUTED TOMOGRAPHIC DIAGNOSIS

- Destructive rhinitis left nasal cavity
- Dysplastic triadan 407 with mild retrograde and antegrade elongation

INTERPRETATION OF THE FINDINGS & FURTHER RECOMMENDATIONS

An underlying cause for the destructive rhinitis cannot be specified – underlying bacterial infection such as Pasteurella sp. is common.

Clinical evaluation of the dentition on a regular basis appears beneficial to monitor abnormal triadan 407.



PATIENT

Rudy Dewicki

SPECIES

Rabbit

BREED

Mixed Breed

SEX

Male Castrated

AGE

8Y, 6M

WEIGHT

1.7kg

INTERPRETED BY

Sebastian Schaub, DVM
Dr. med. vet.
DipECVDI

IMAGING PERFORMED BY

Rachel Jacobs and
Ivana Levy

HOSPITAL NAME

Emergency Veterinary
Hospital of Ann Arbor

REFERRING VET

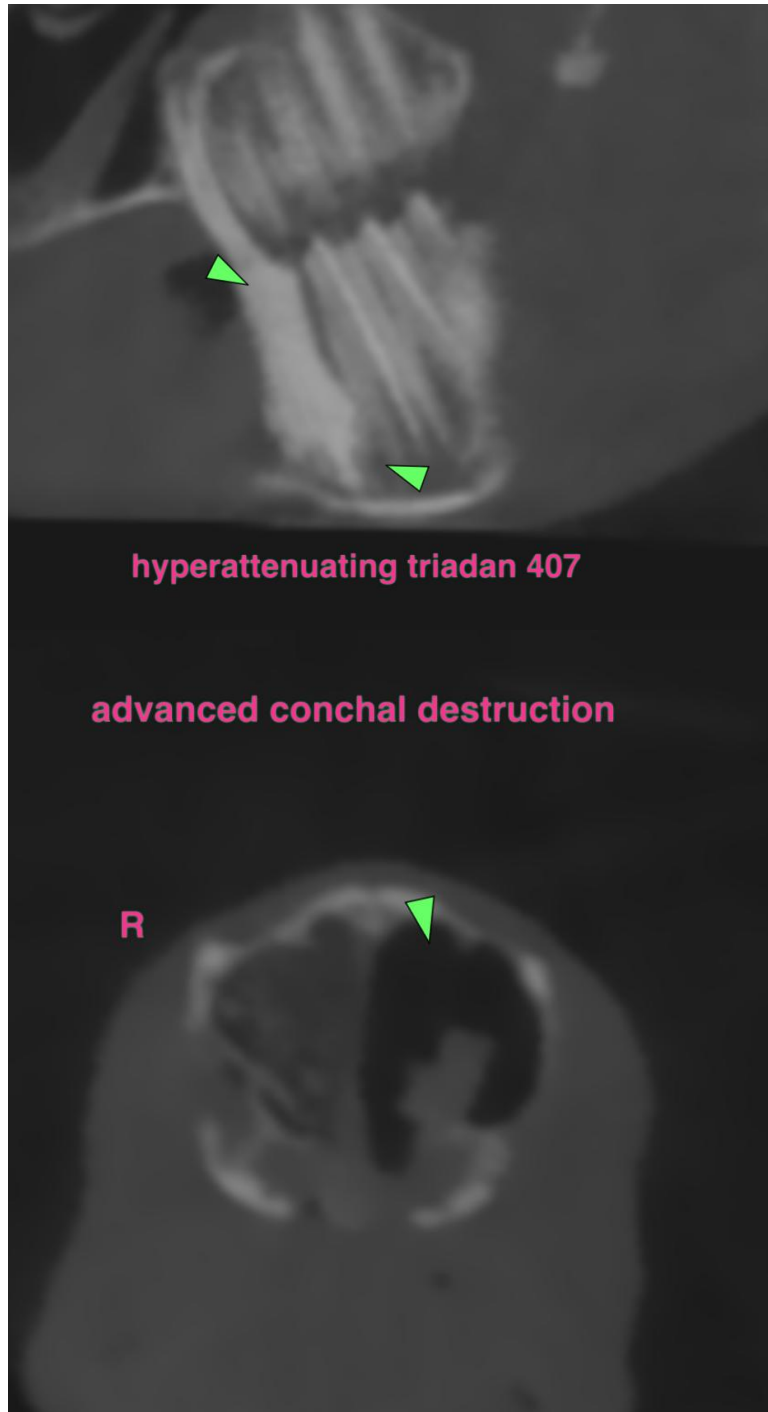
Ivana Levy

INVOICE

75259

DATE

6-2-26



The information and recommendations provided are based on the images presented by the referring veterinarian/sonographer. No evaluation can be communicated regarding pathology that was not



PATIENT

Rudy Dewicki

SPECIES

Rabbit

BREED

Mixed Breed

SEX

Male Castrated

AGE

8Y, 6M

WEIGHT

1.7kg

INTERPRETED BY

Sebastian Schaub, DVM
Dr. med. vet.
DipECVDI

IMAGING PERFORMED BY

Rachel Jacobs and
Ivana Levy

HOSPITAL NAME

Emergency Veterinary
Hospital of Ann Arbor

REFERRING VET

Ivana Levy

INVOICE

75259

DATE

6-2-26

visible in the image/video clips provided.

Thank you for this referral. If the clinical or image interpretation does not parallel your findings or if I can be of any further assistance please contact me.

Sebastian Schaub, Sebastian Schaub, DVM, Dr. med. vet. DipECVDI
info@sonopath.com